

# Congenital

Prof. Vivek Muthurangu

Professor of Cardiovascular Imaging & MR Physics - UCL

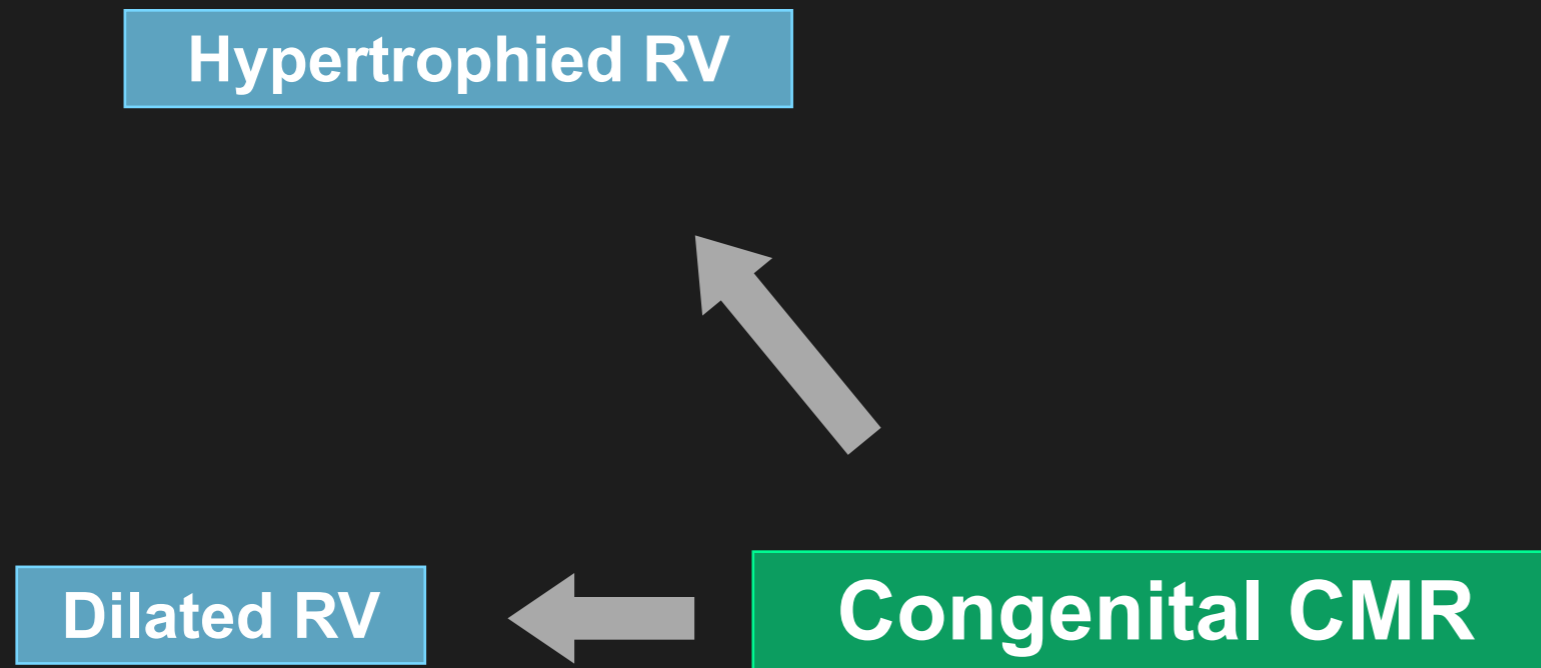


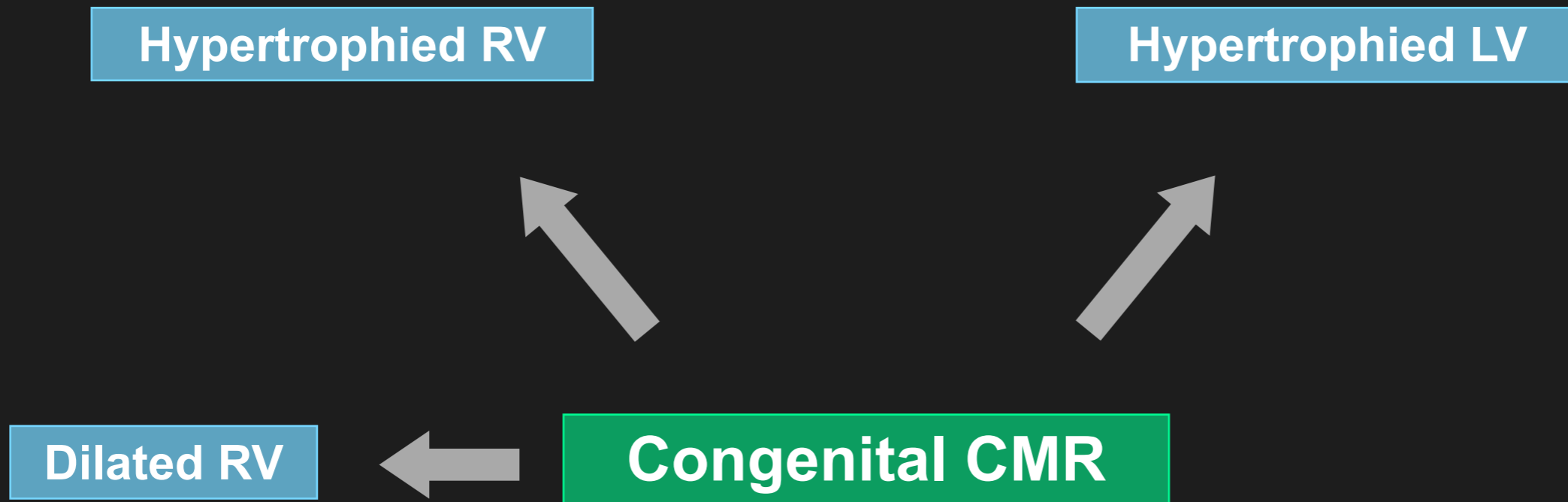
**EACVI**  
European Association of  
Cardiovascular Imaging

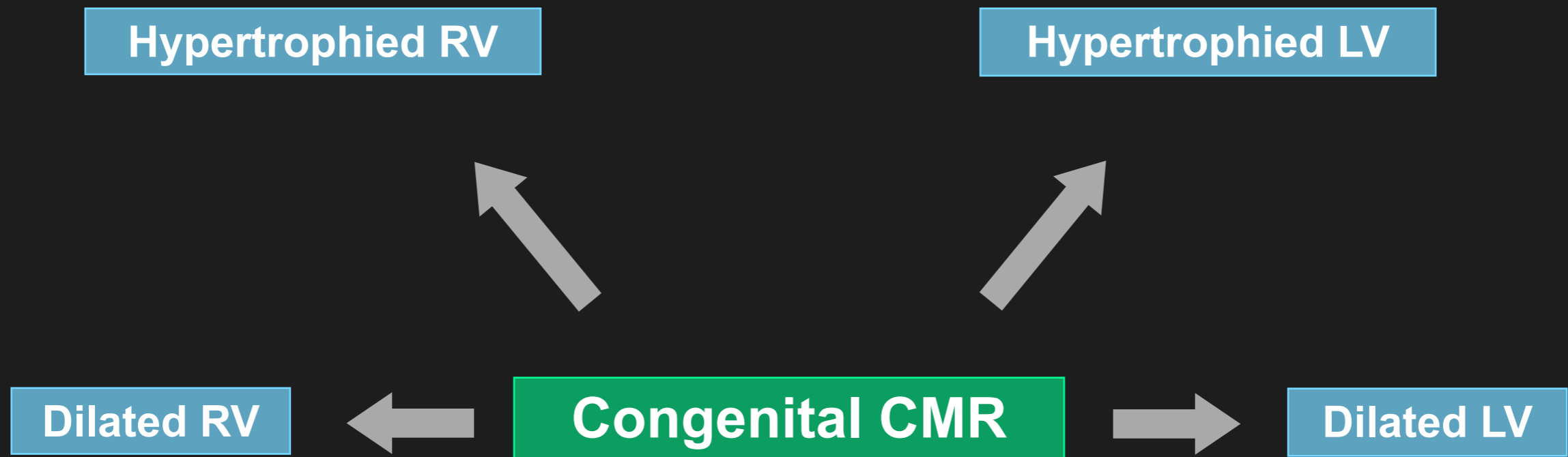


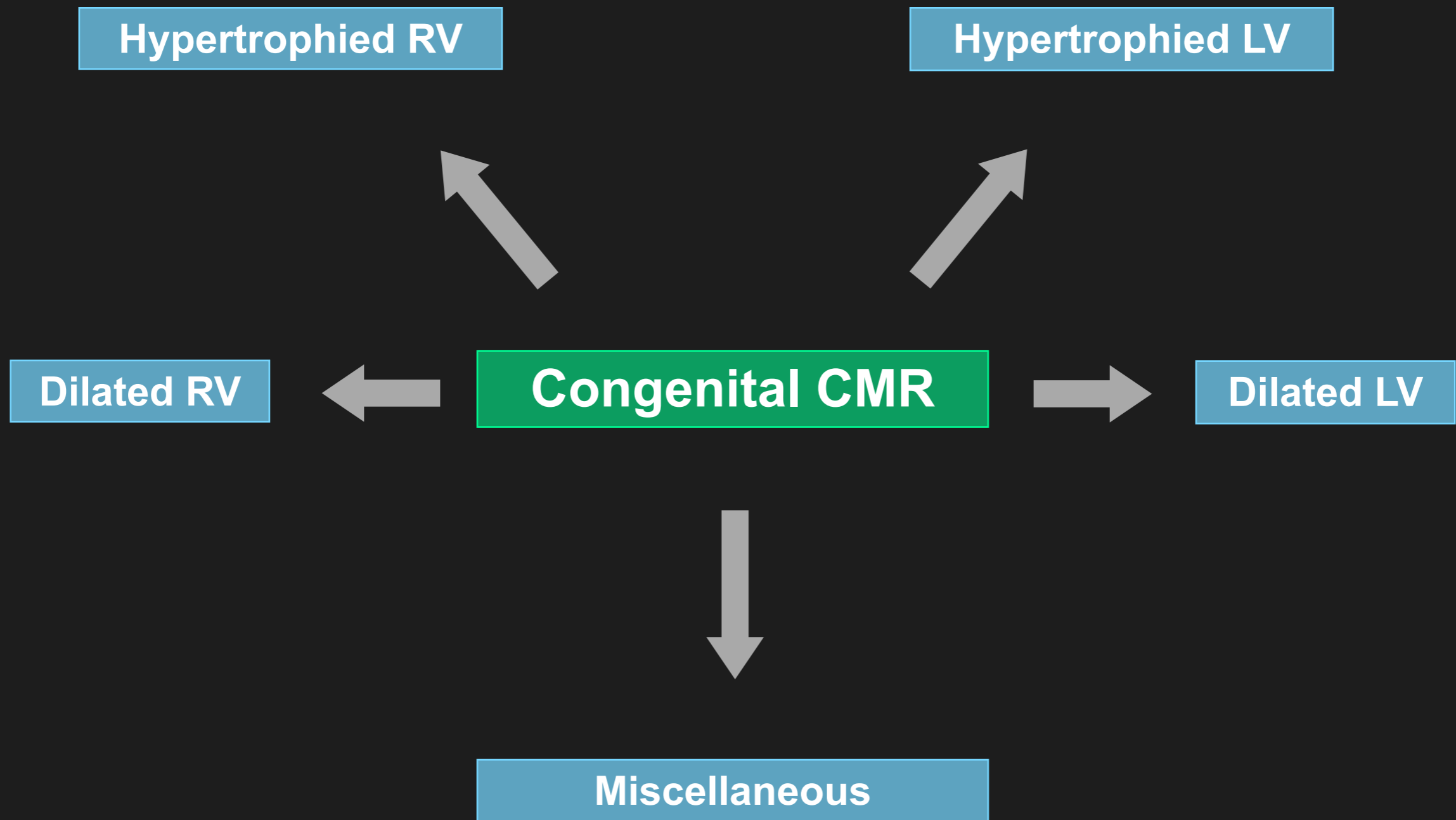
## Congenital CMR





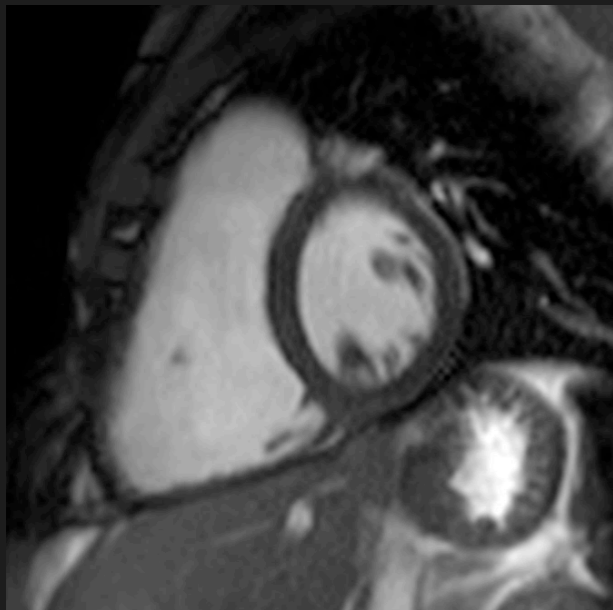
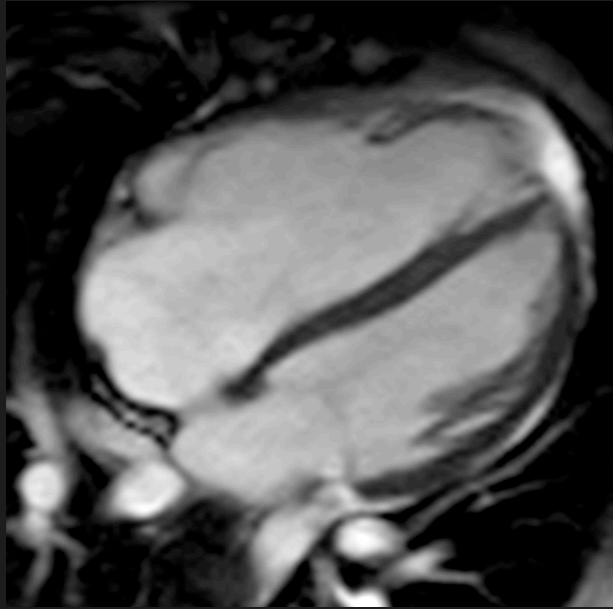




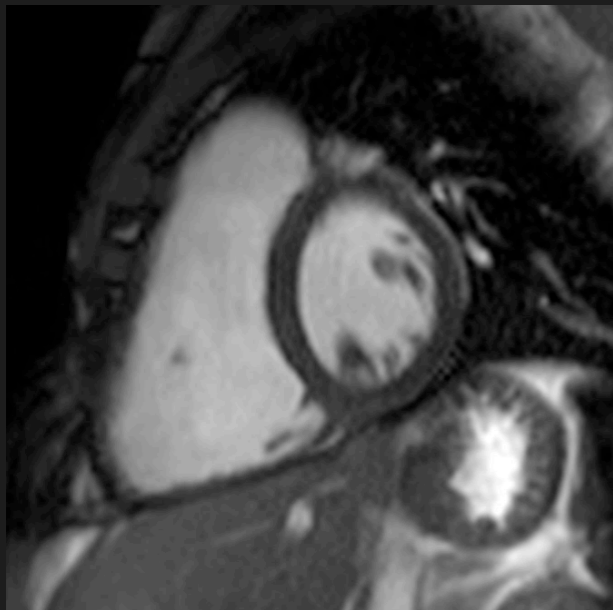
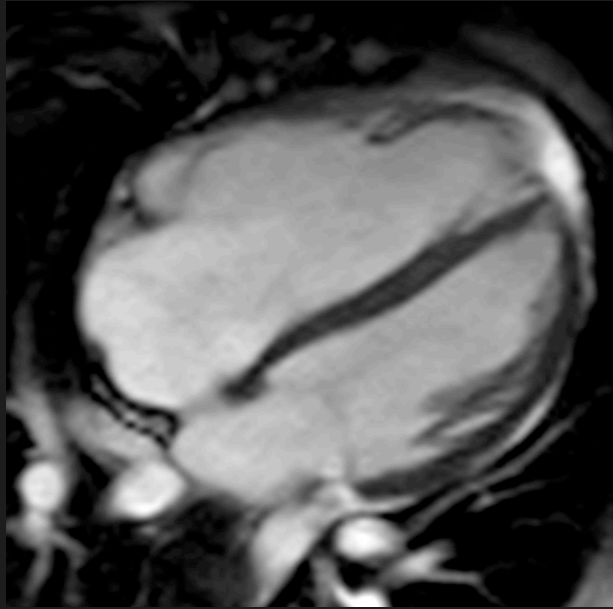




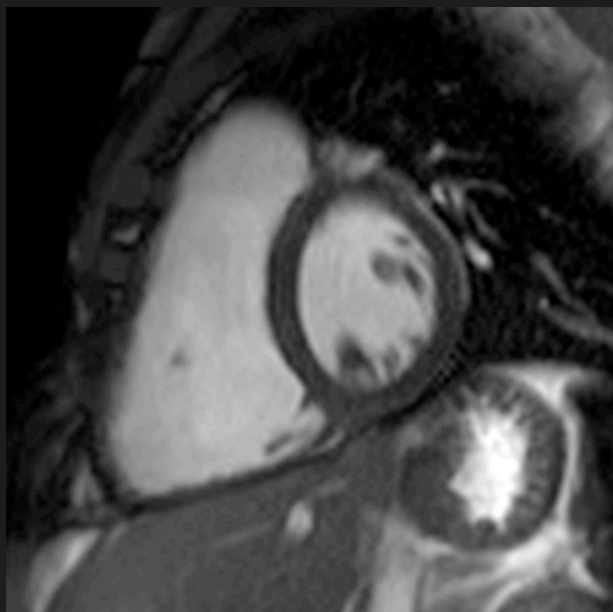
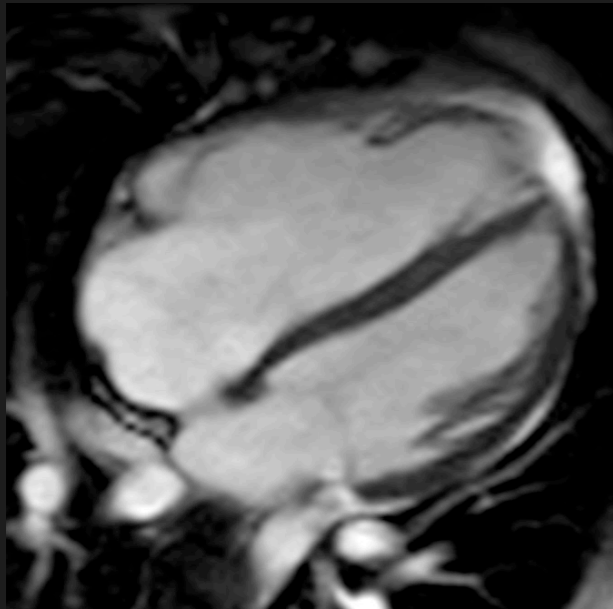
## Right heart dilation - ?ARVC



## Right heart dilation - ?ARVC

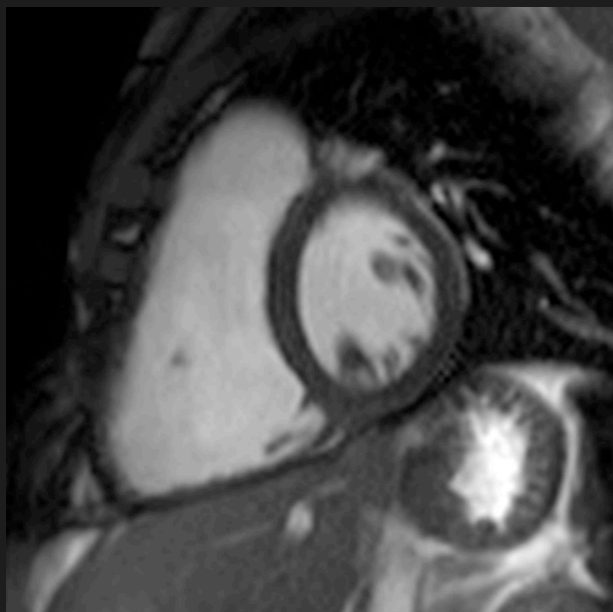
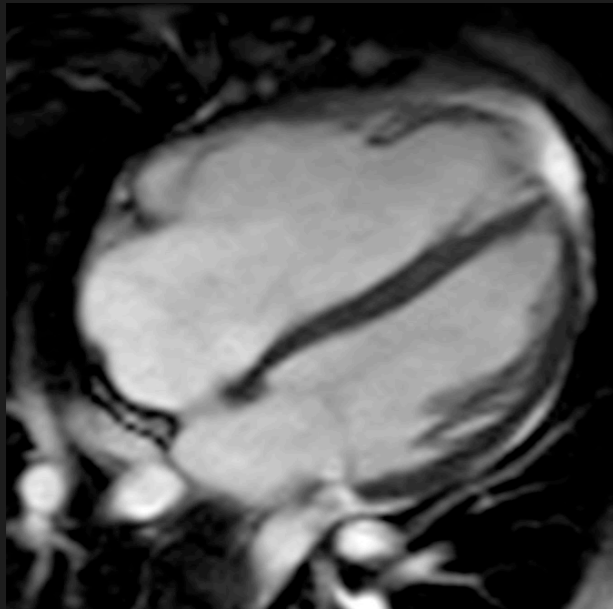


## Right heart dilation - ?ARVC



Normal function

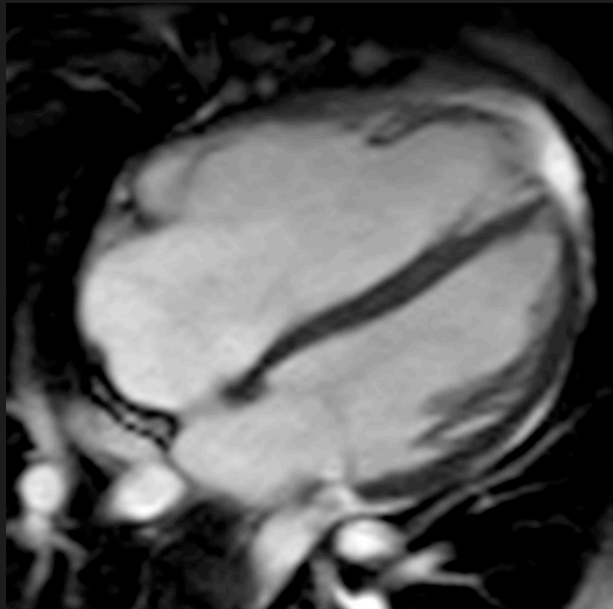
## Right heart dilation - ?ARVC



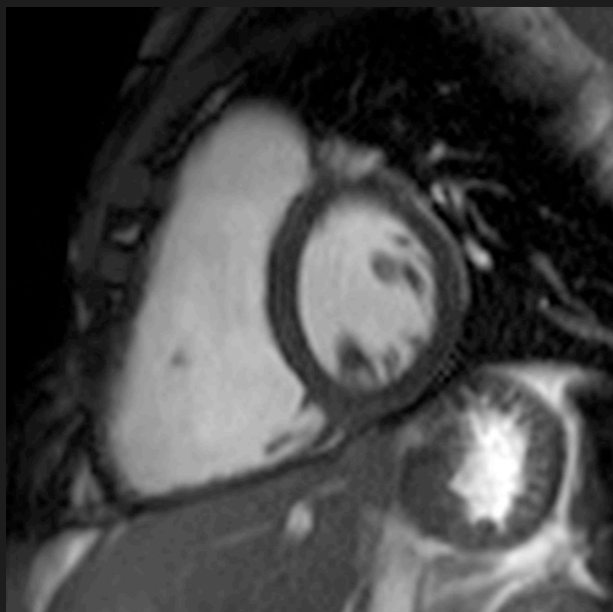
Normal function

Could it be congenital?

Right heart dilation - ?ARVC



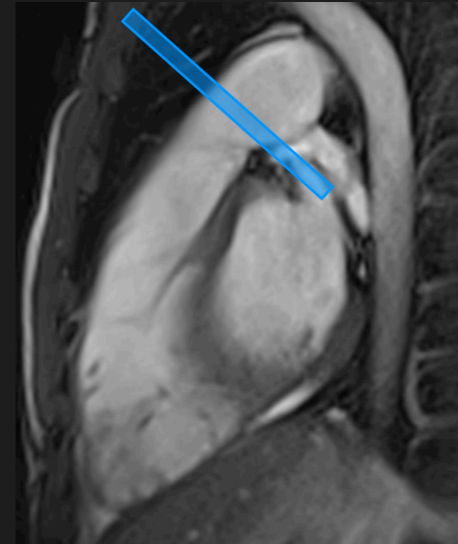
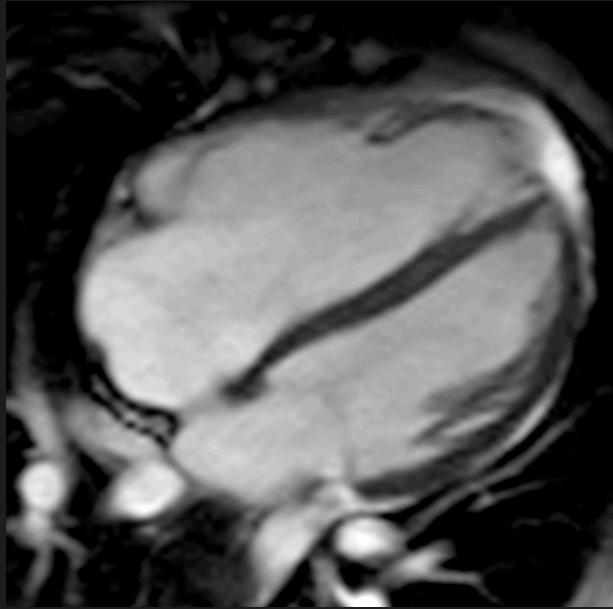
Shunt?



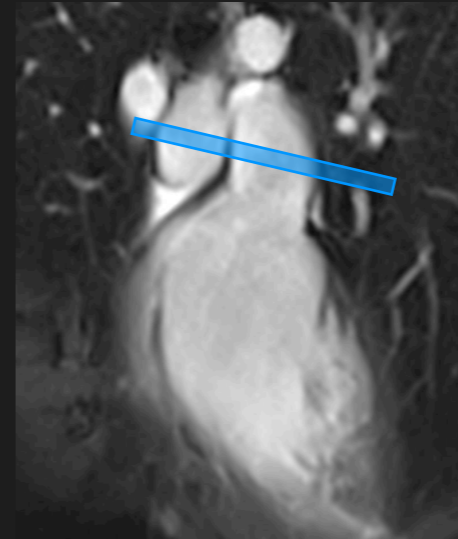Normal function

Could it be congenital?

Right heart dilation - ?ARVC



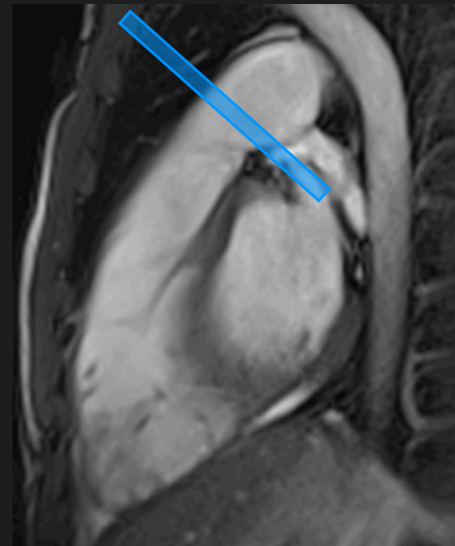
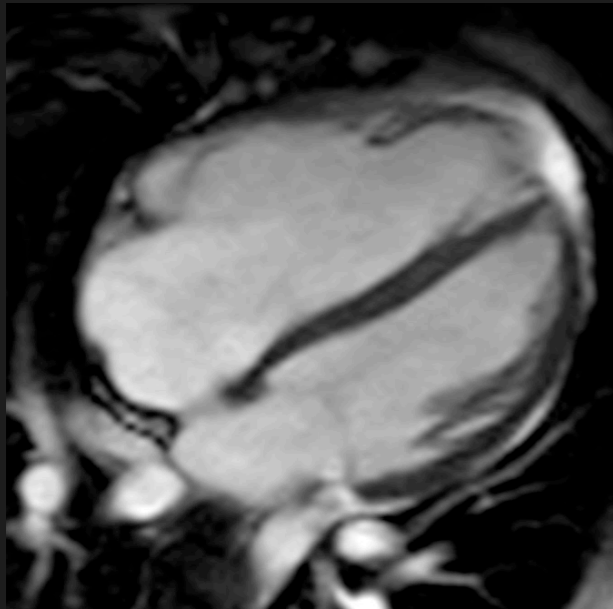
Shunt?



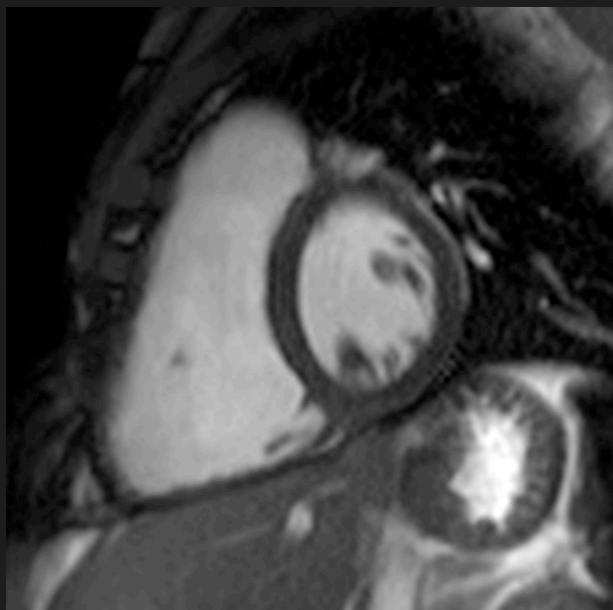
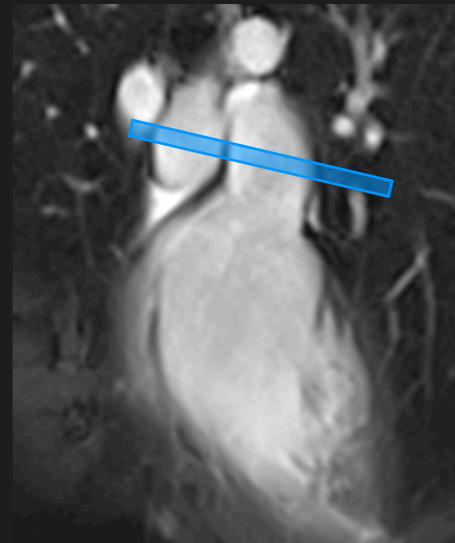
Normal function

Could it be congenital?

Right heart dilation - ?ARVC




Shunt?

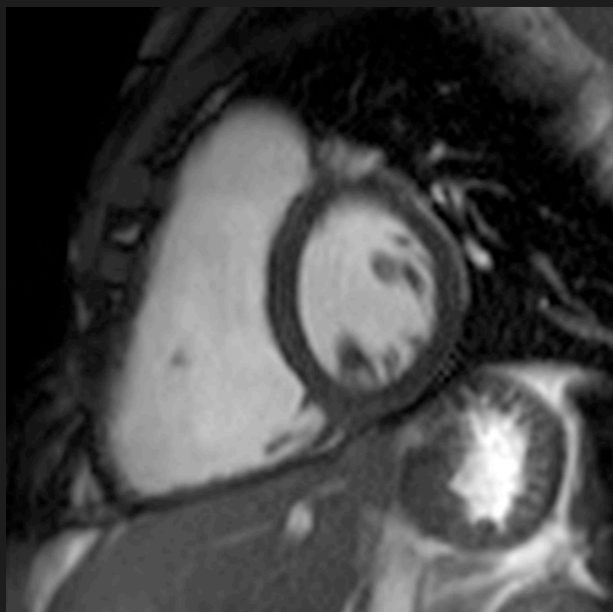
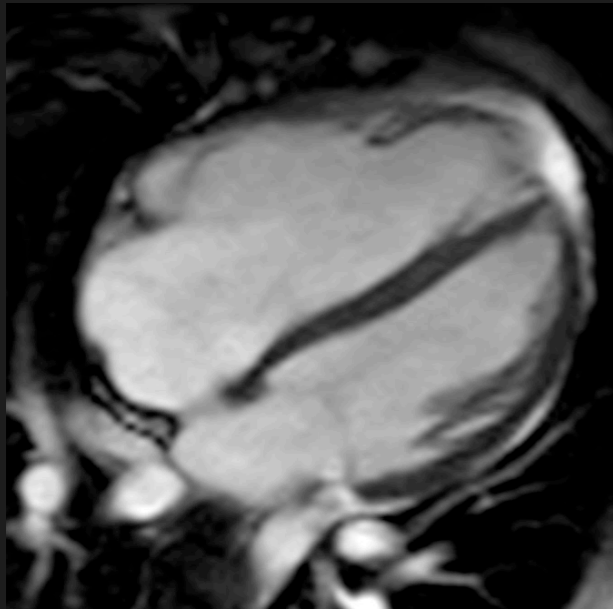


Normal function

Could it be congenital?




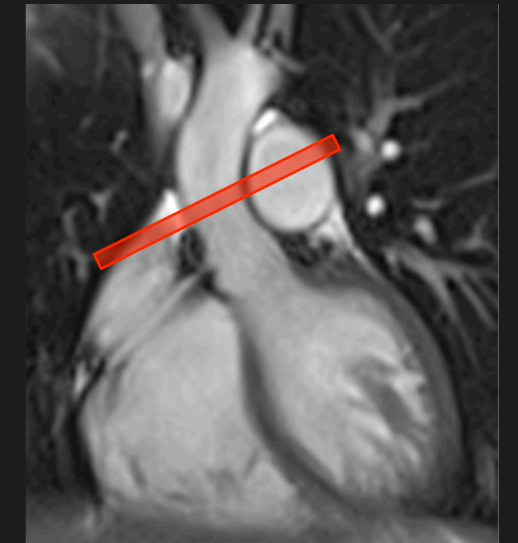
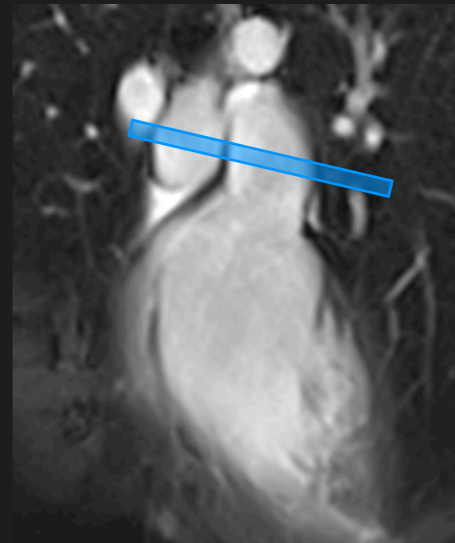
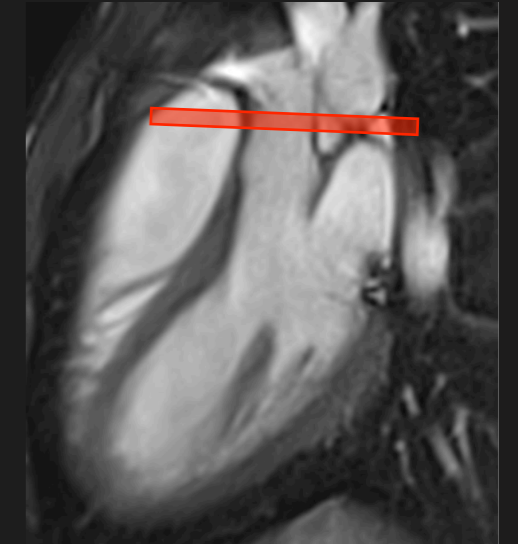
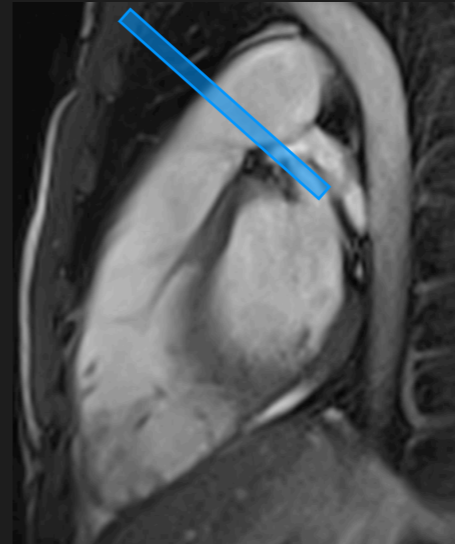
Right heart dilation - ?ARVC



Normal function

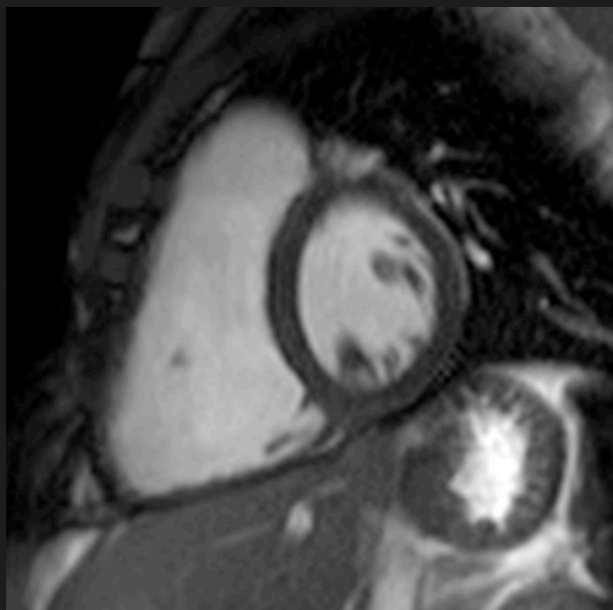
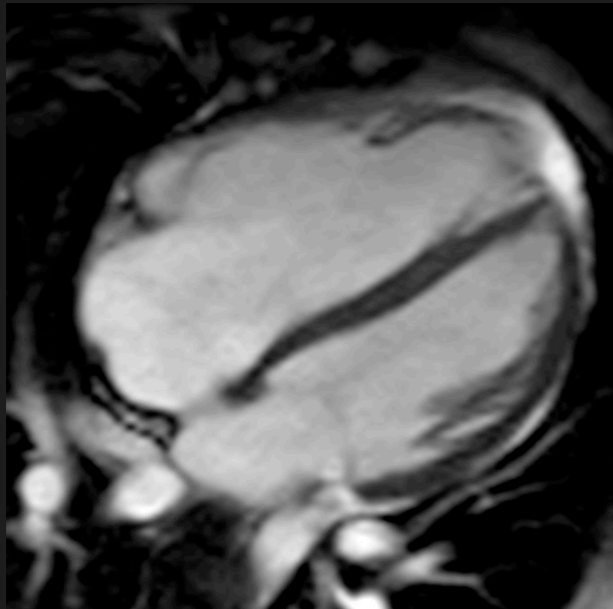
Could it be congenital?

Shunt?







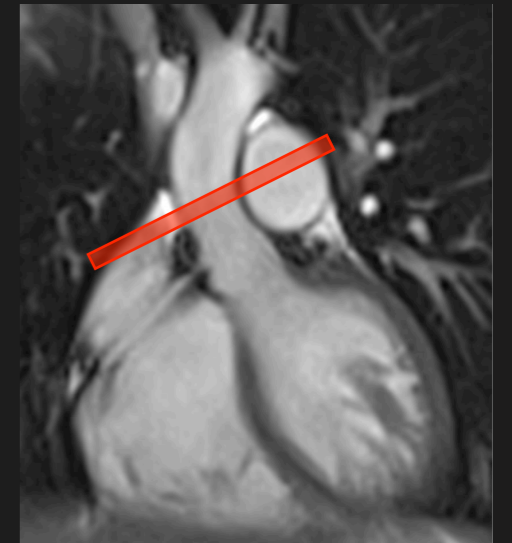
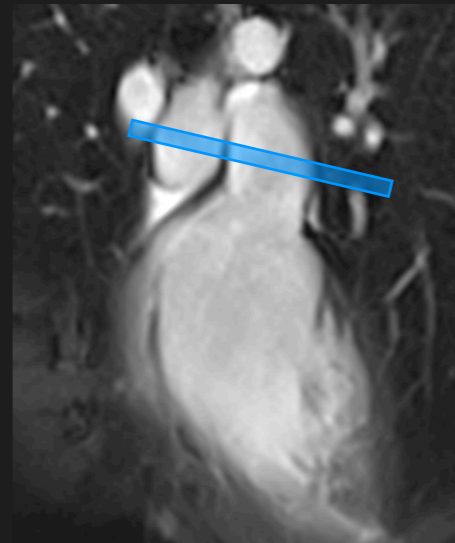
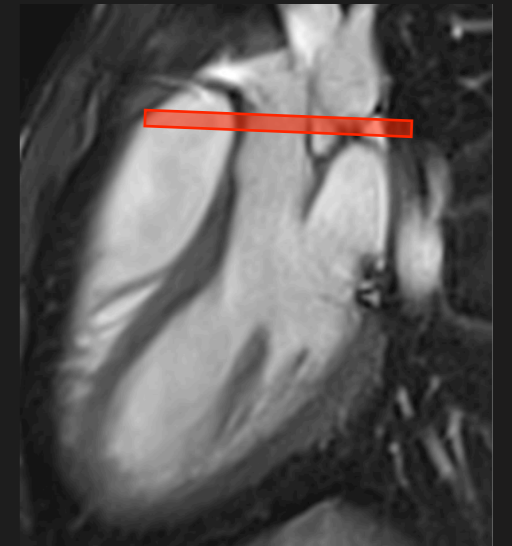
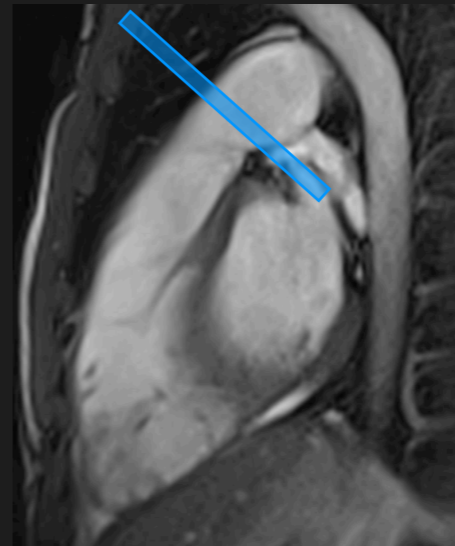
Right heart dilation - ?ARVC



Normal function

Could it be congenital?

Shunt?







Ao Stroke Volume	50 mls
PA Stroke Volume	100 mls

Ao Stroke Volume	50 mls
PA Stroke Volume	100 mls

$$Q_p:Q_s = 2:1$$

Ao Stroke Volume	50 mls
PA Stroke Volume	100 mls

$$Q_p:Q_s = 2:1$$

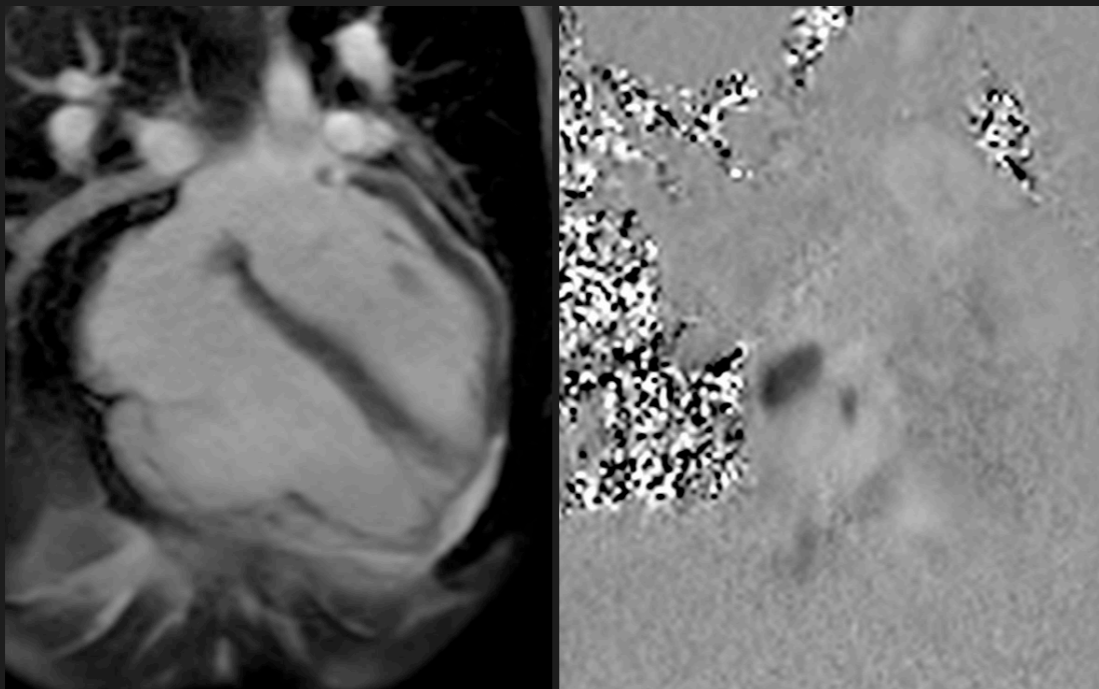
LV Stroke Volume	50 mls
RV Stroke Volume	100 mls

Ao Stroke Volume	50 mls
PA Stroke Volume	100 mls

$$Q_p:Q_s = 2:1$$

LV Stroke Volume	50 mls
RV Stroke Volume	100 mls

Shunt before AV valve



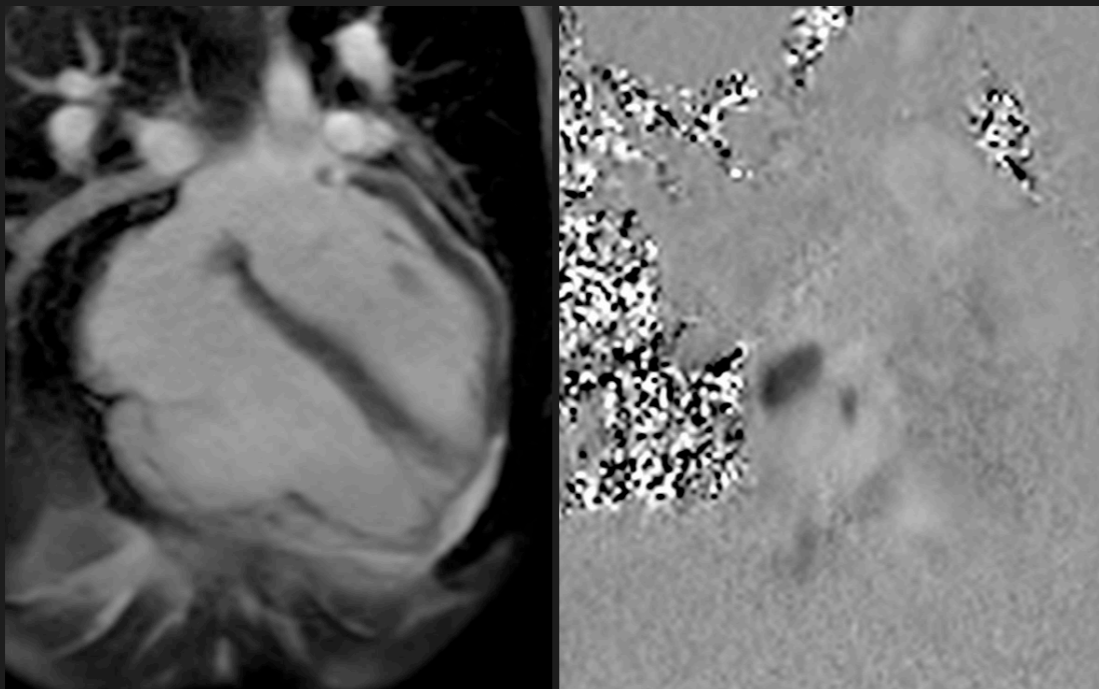
Ao Stroke Volume	50 mls
PA Stroke Volume	100 mls

$$Q_p:Q_s = 2:1$$

LV Stroke Volume	50 mls
RV Stroke Volume	100 mls

Shunt before AV valve

$$RVSV = PASV$$





Ao Stroke Volume	50 mls
PA Stroke Volume	100 mls

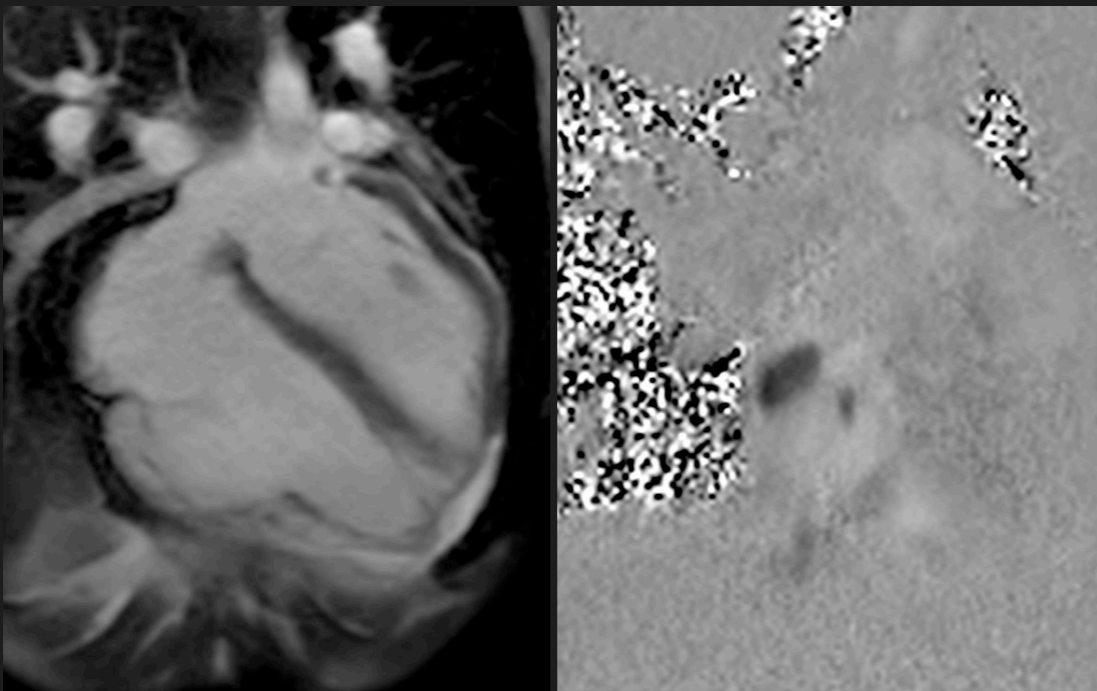
$$Q_p:Q_s = 2:1$$

LV Stroke Volume	50 mls
RV Stroke Volume	100 mls

Shunt before AV valve

$$RVSV = PASV$$

RV volume load - high EDV



Ao Stroke Volume	50 mls
PA Stroke Volume	100 mls

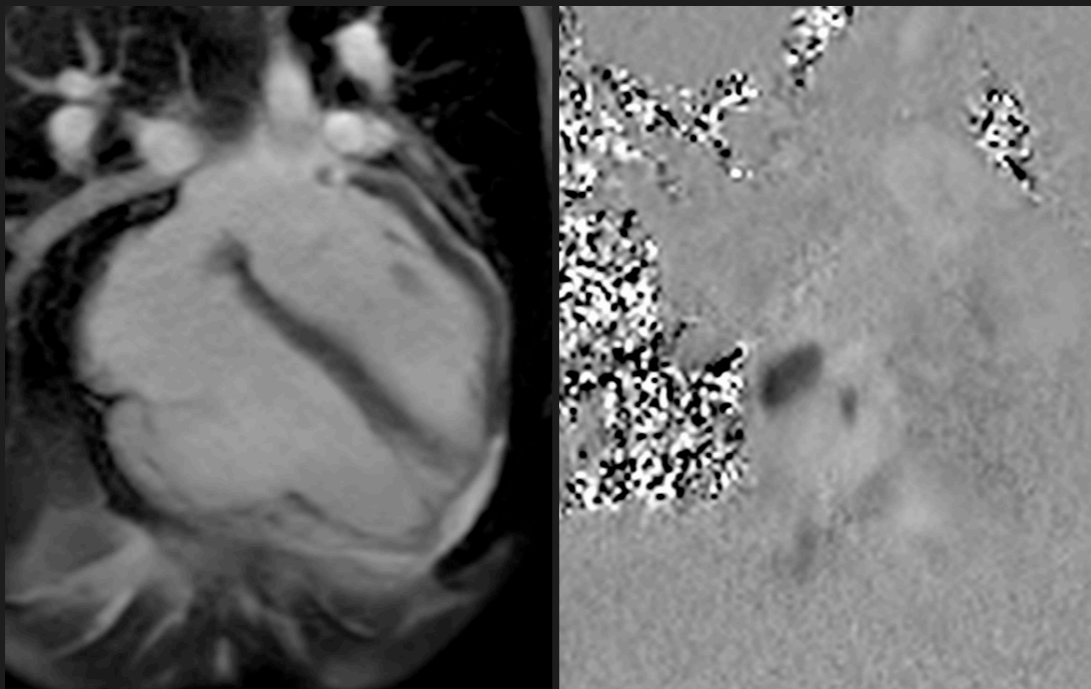
$Q_p:Q_s = 2:1$

LV Stroke Volume	50 mls
RV Stroke Volume	100 mls

Shunt before AV valve

$RVSV = PASV$

RV volume load - high EDV

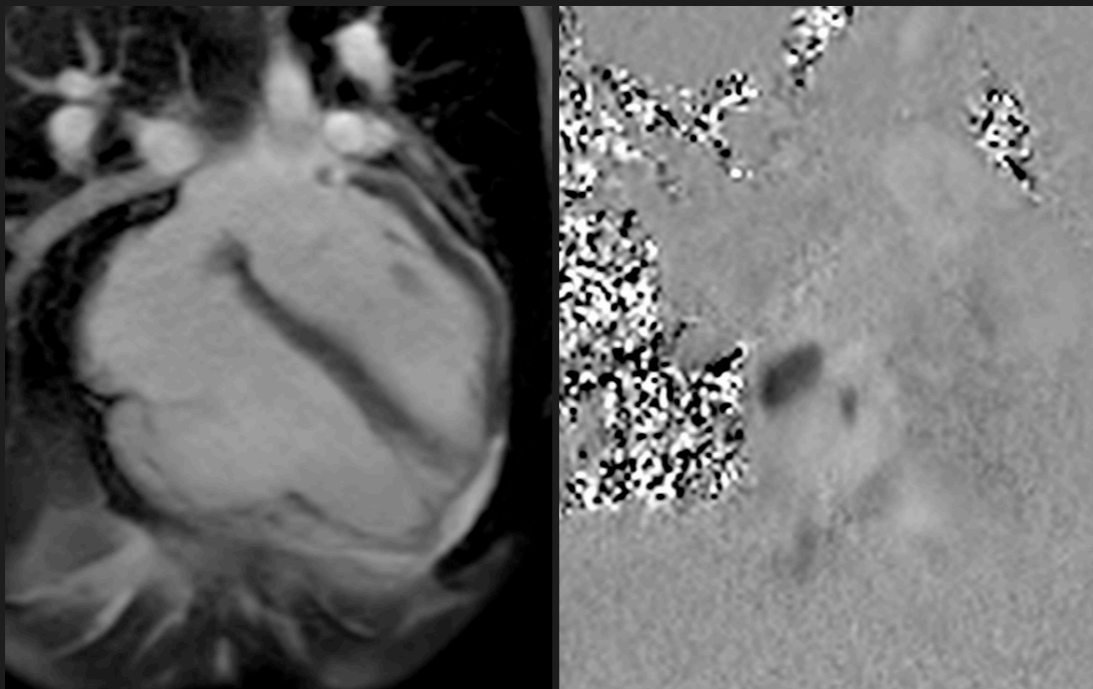


Not always simple

Ao Stroke Volume	50 mls
PA Stroke Volume	100 mls

$Q_p:Q_s = 2:1$

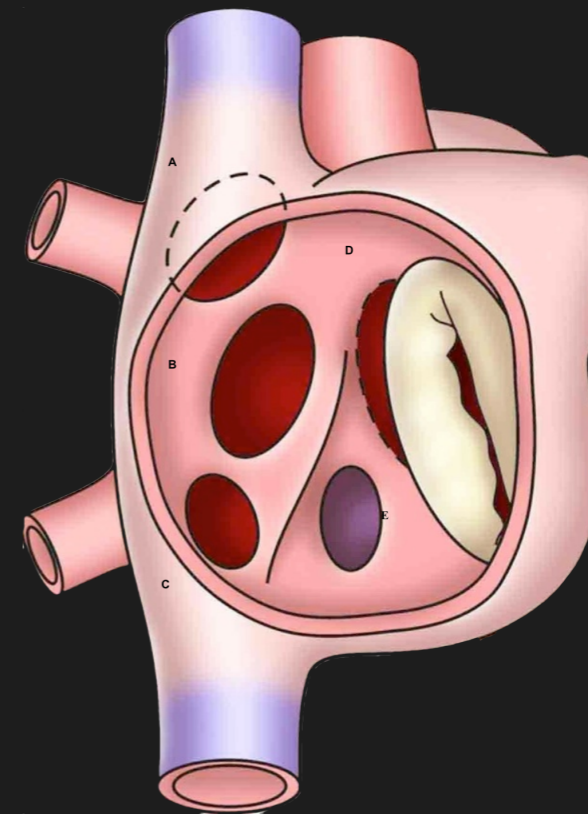
LV Stroke Volume	50 mls
RV Stroke Volume	100 mls



Shunt before AV valve

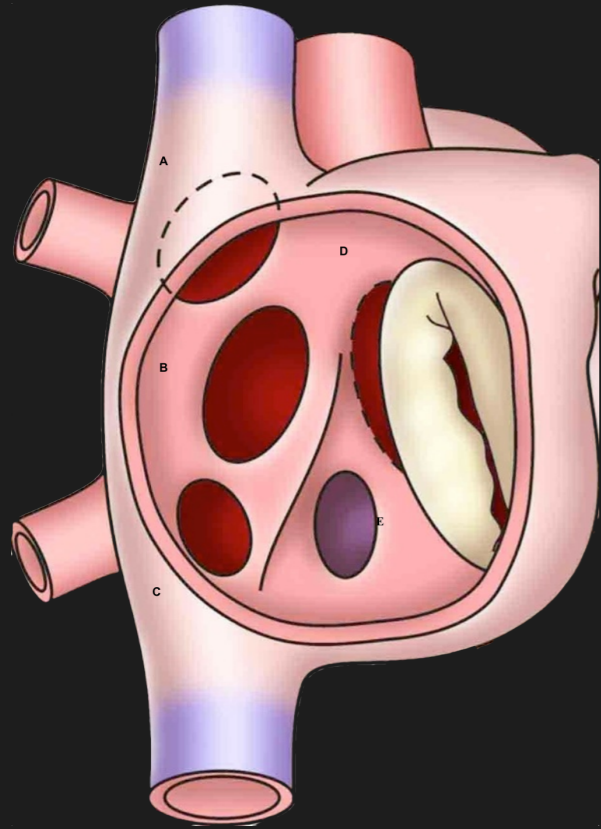
$RVSV = PASV$

RV volume load - high EDV

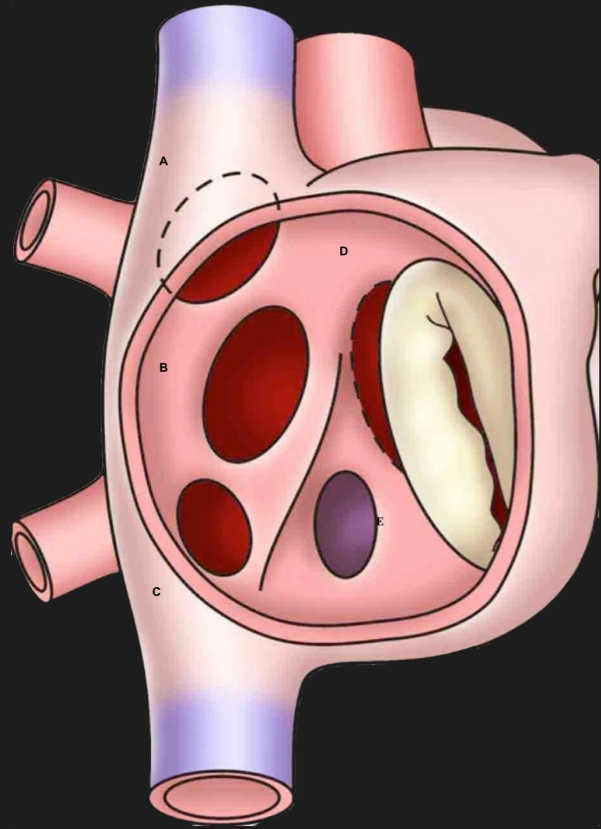


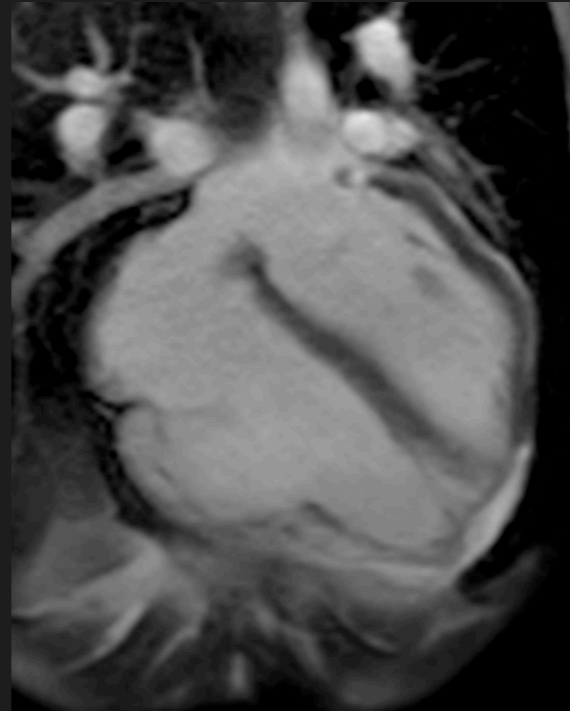
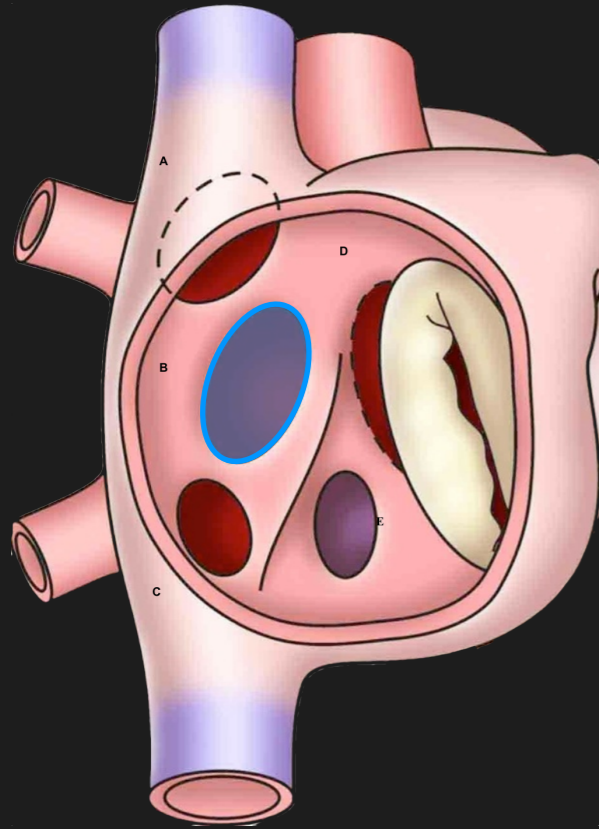
Not always simple

# Right heart dilation - ASD

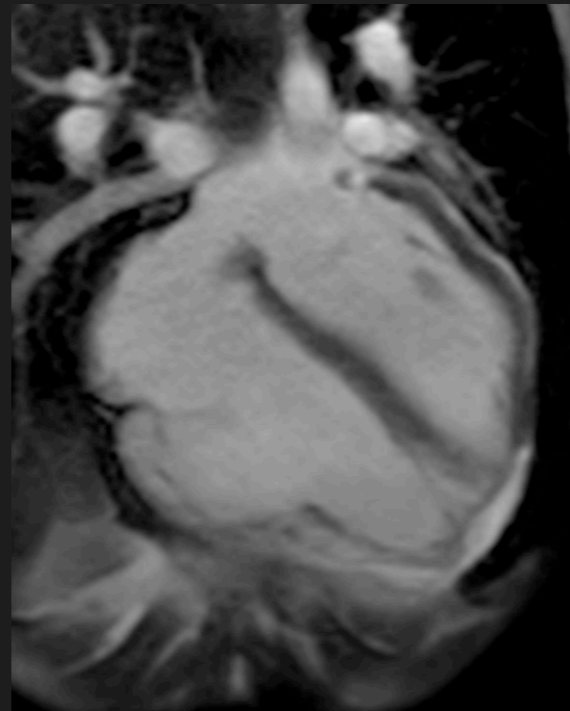
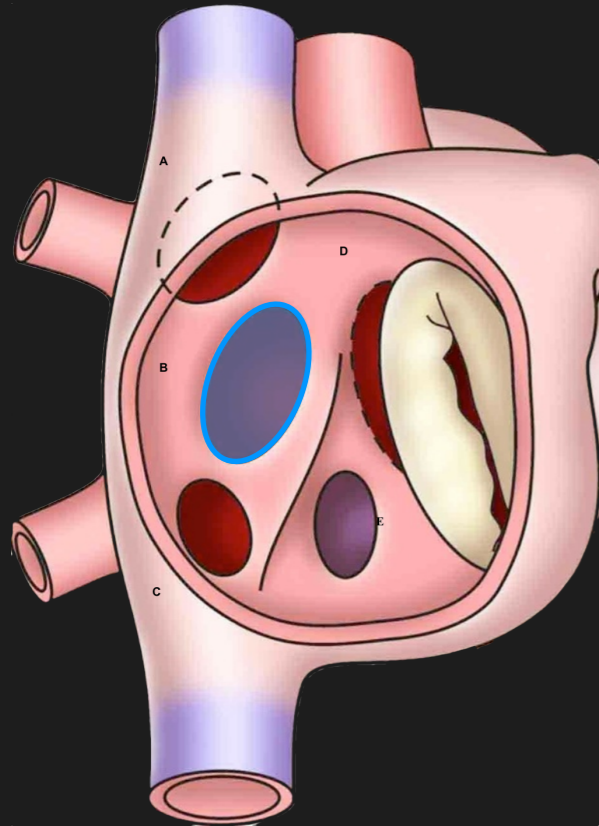


# Right heart dilation - ASD

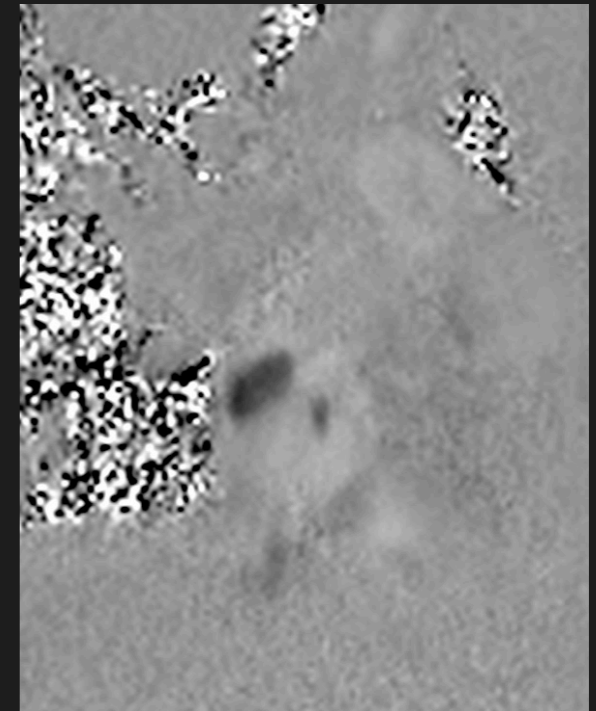




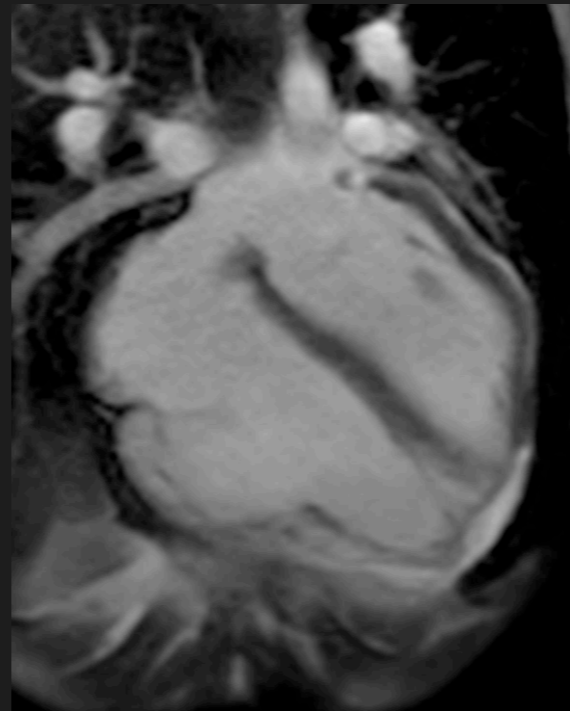
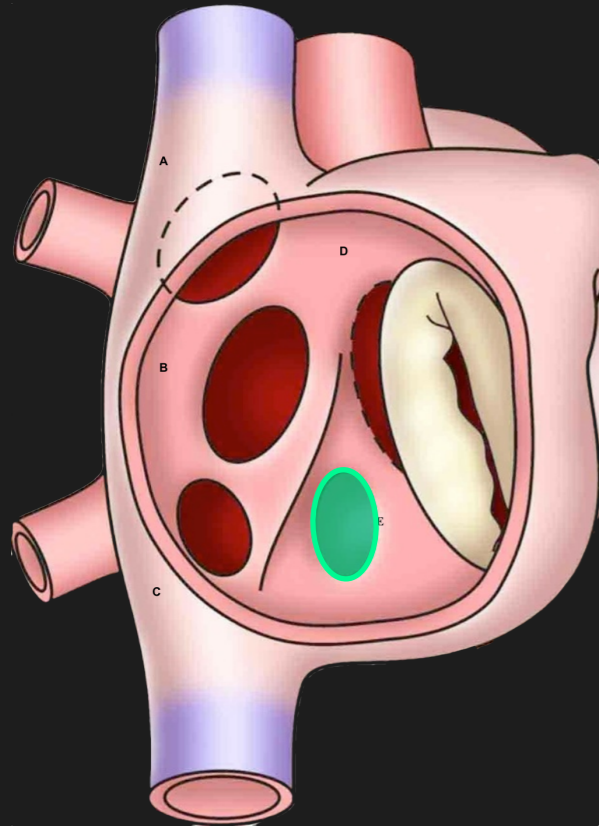
**Secundum defect**



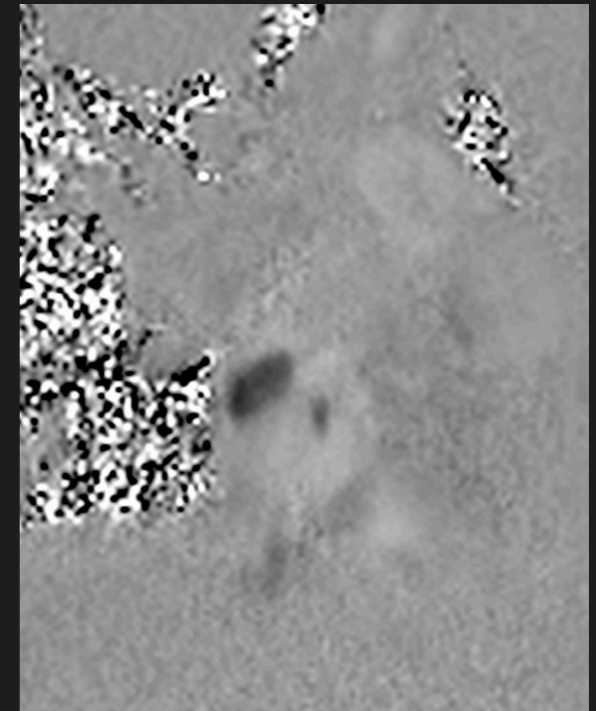
**Secundum defect**



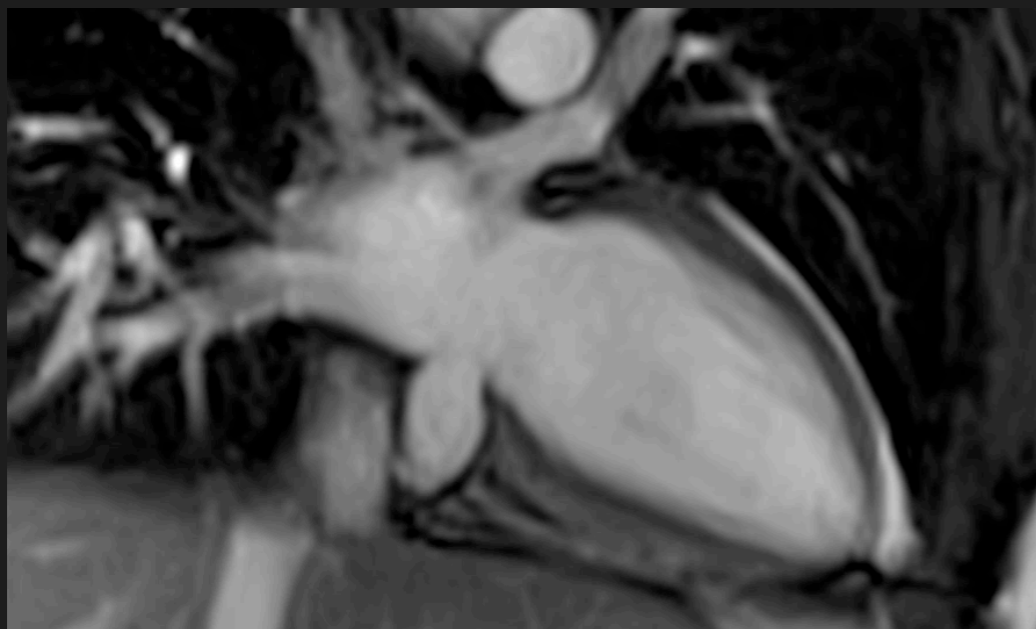
**TP - PCMR**



Secundum defect

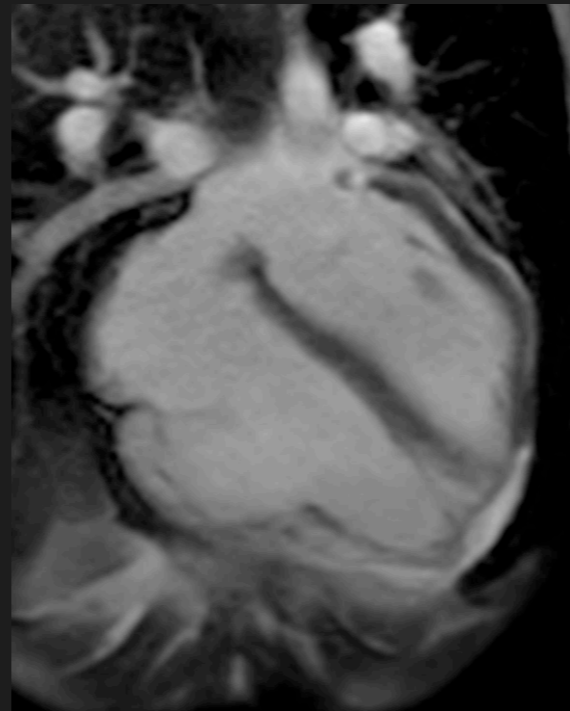
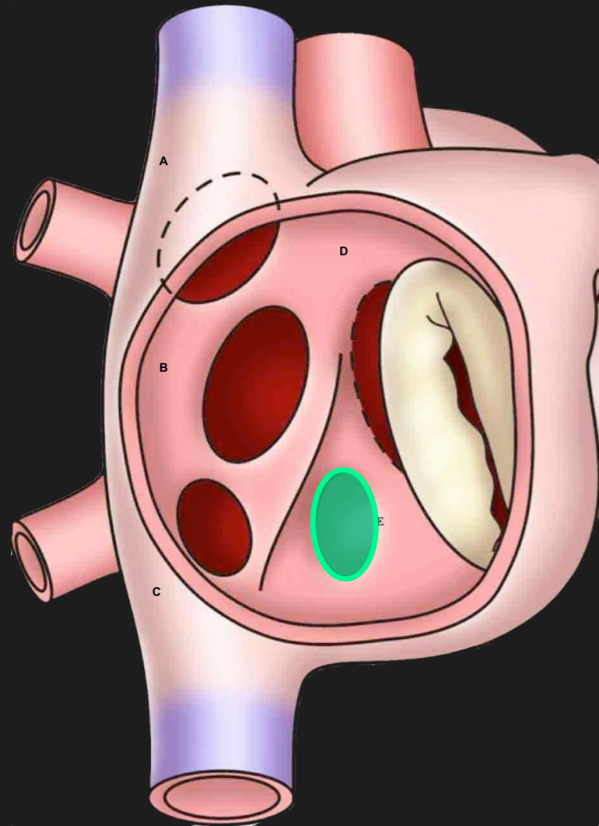


TP - PCMR

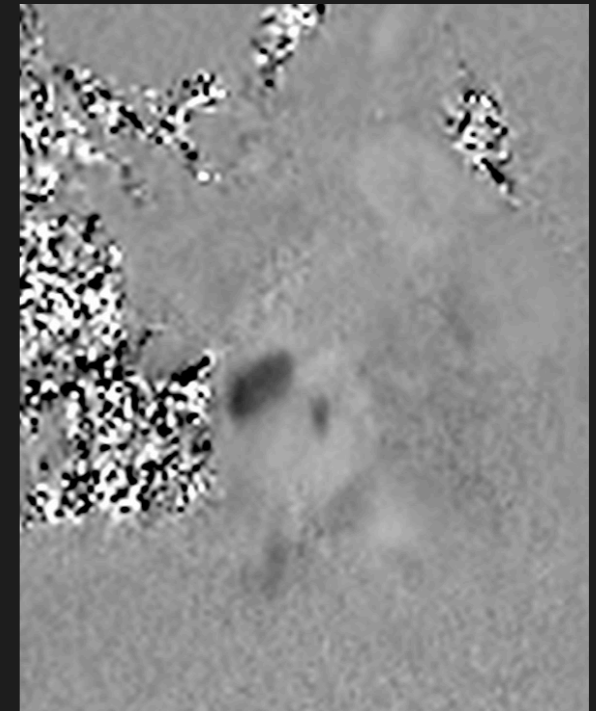


Unroofed CS

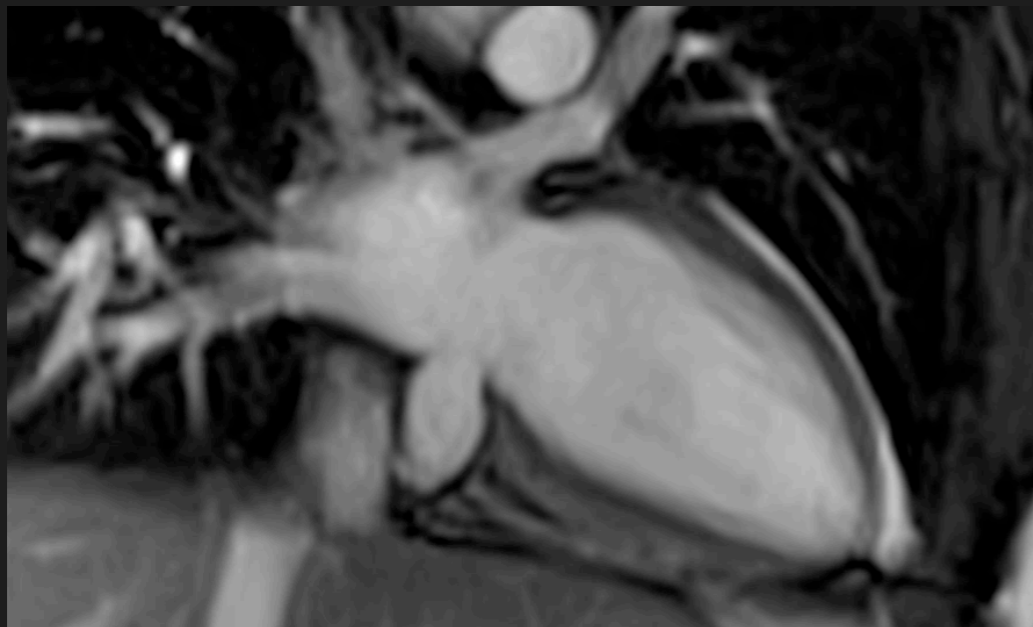




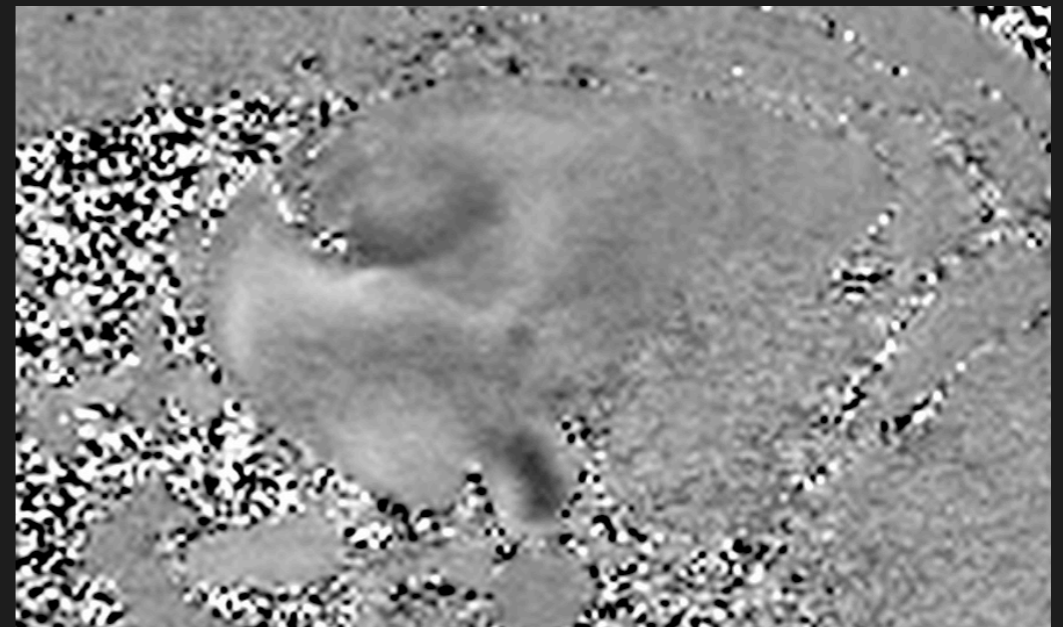
Secundum defect



TP - PCMR



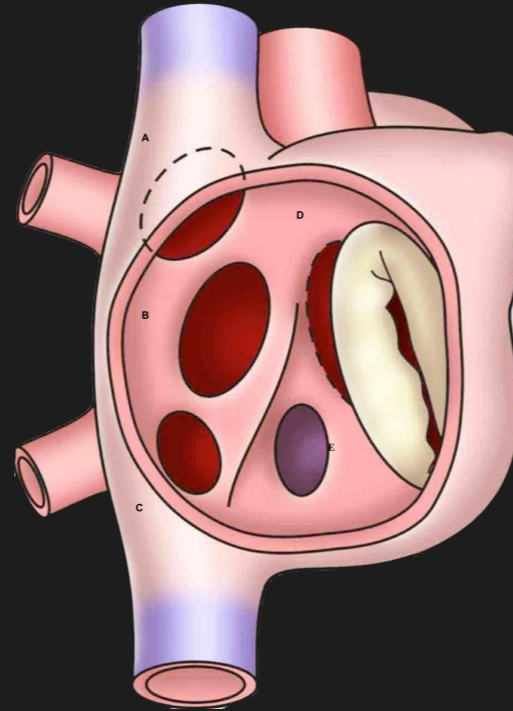
Unroofed CS



TP - PCMR

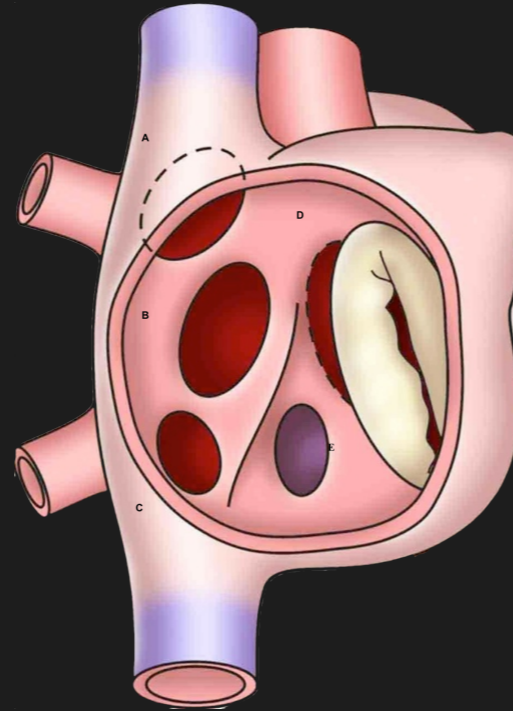
$Q_p:Q_s > 1$

$RVSV = PASV$



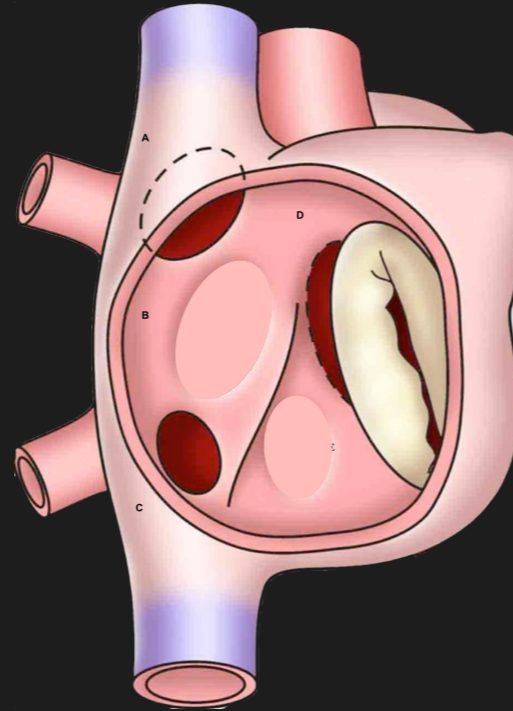
$Q_p:Q_s > 1$

$RVSV = PASV$



$Q_p:Q_s > 1$

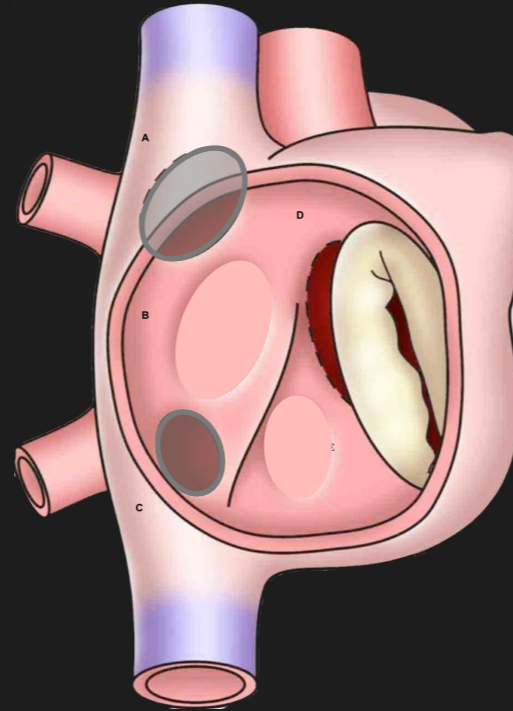
$RVSV = PASV$



**$Q_p:Q_s > 1$**

**$RVSV = PASV$**

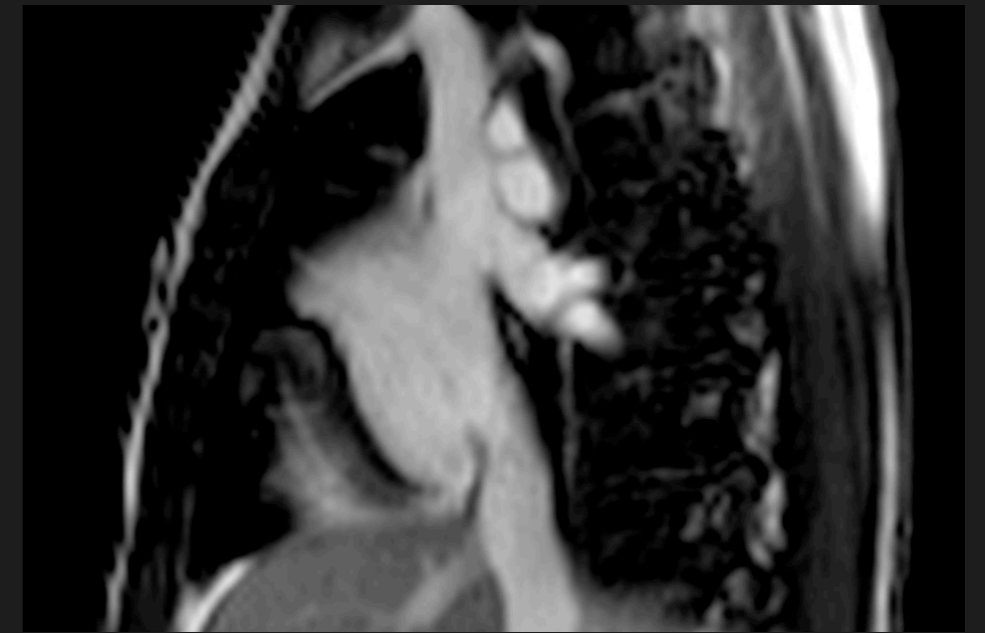
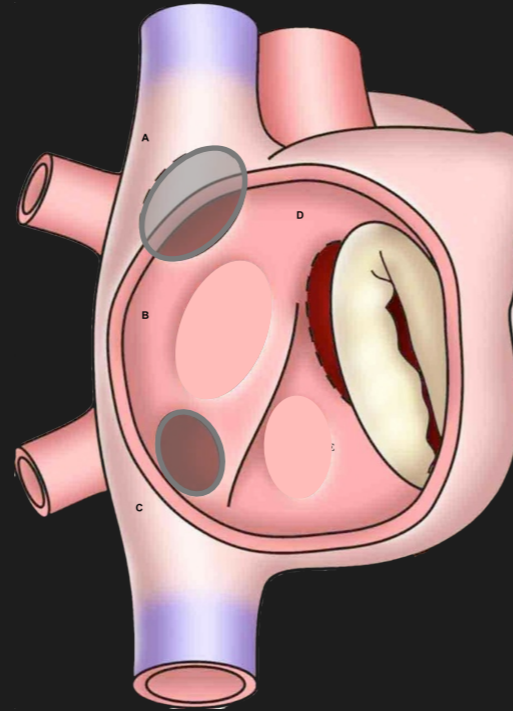
**Look around**



$Q_p:Q_s > 1$

$RVSV = PASV$

Look around

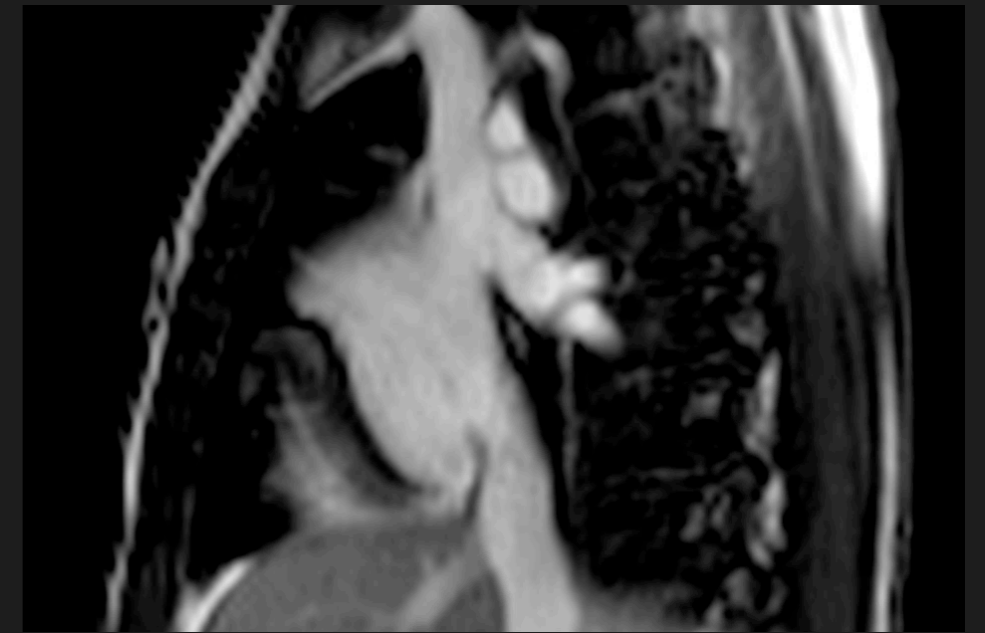
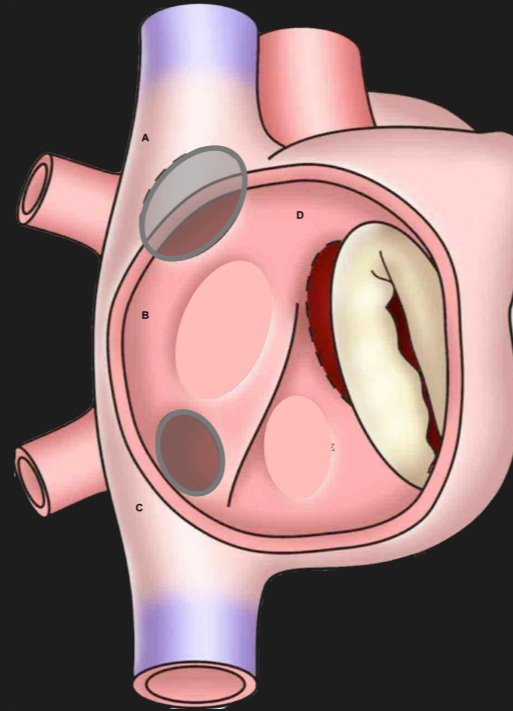


Sinus Venosus

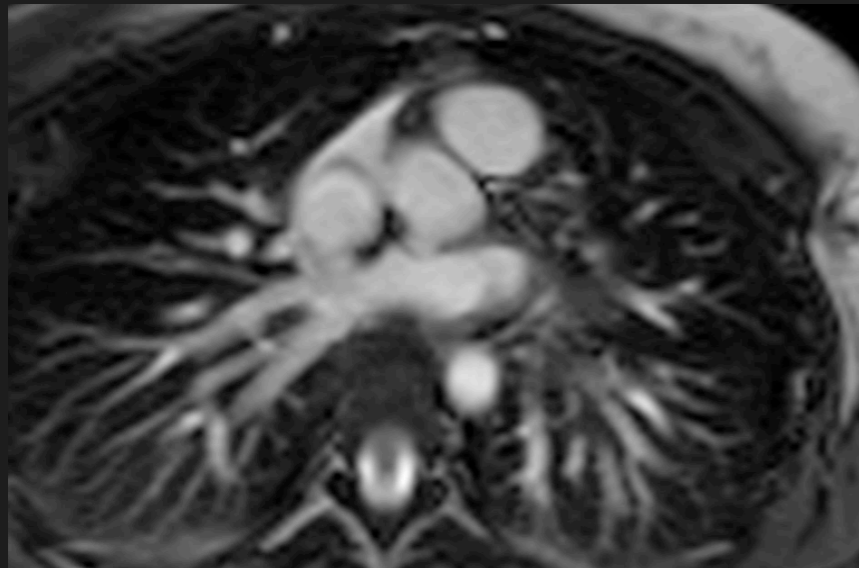
$Q_p:Q_s > 1$

$RVSV = PASV$

Look around



Sinus Venosus

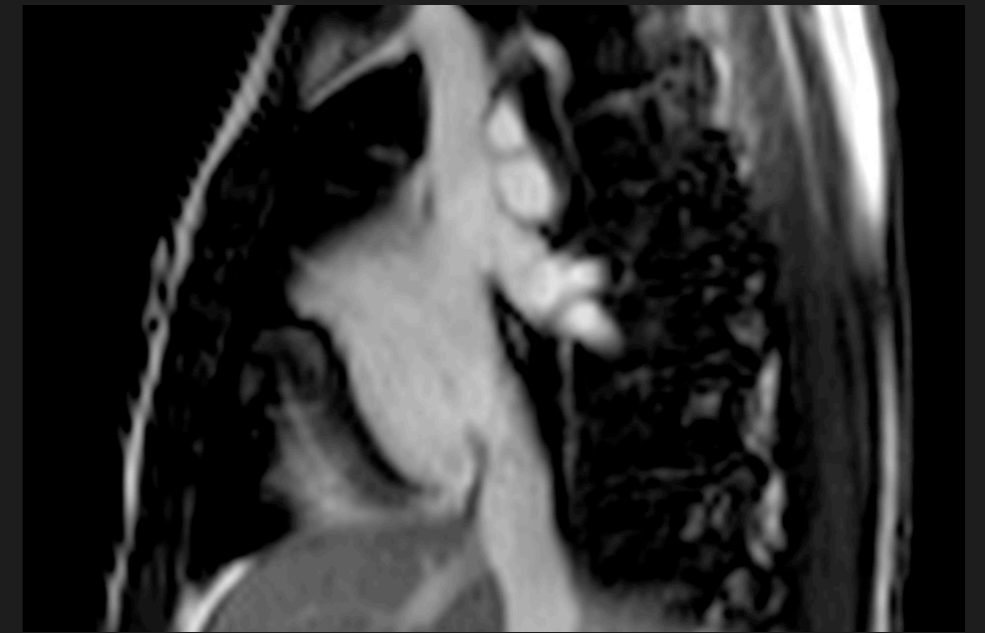
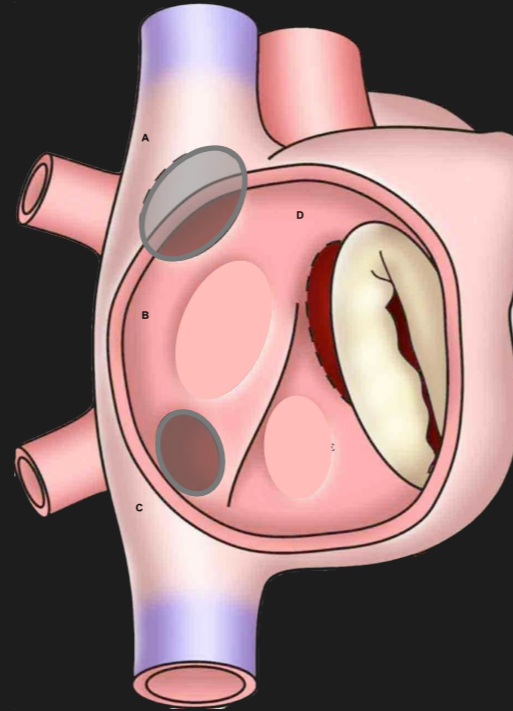


PAPVD

$Q_p:Q_s > 1$

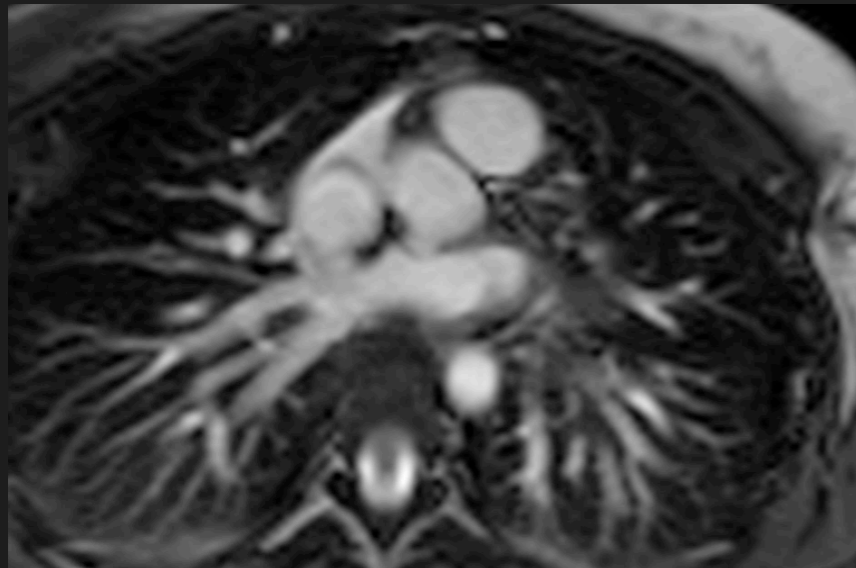
$RVSV = PASV$

Look around



Sinus Venosus

PV blood into RA



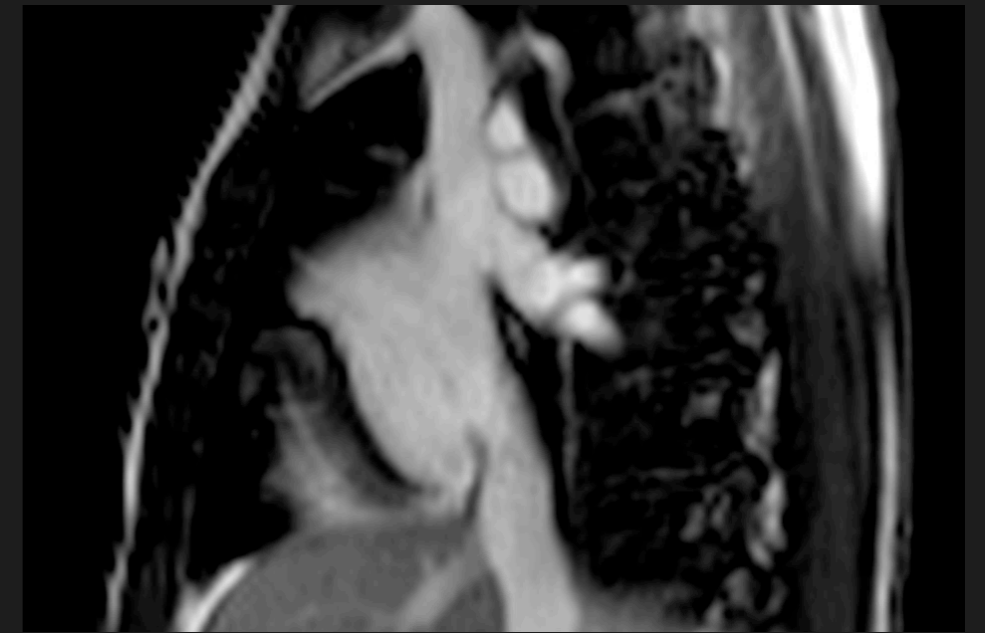
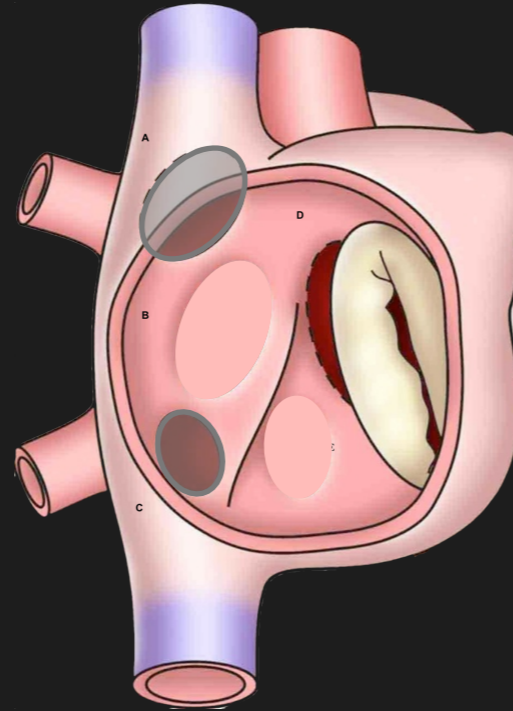
PAPVD



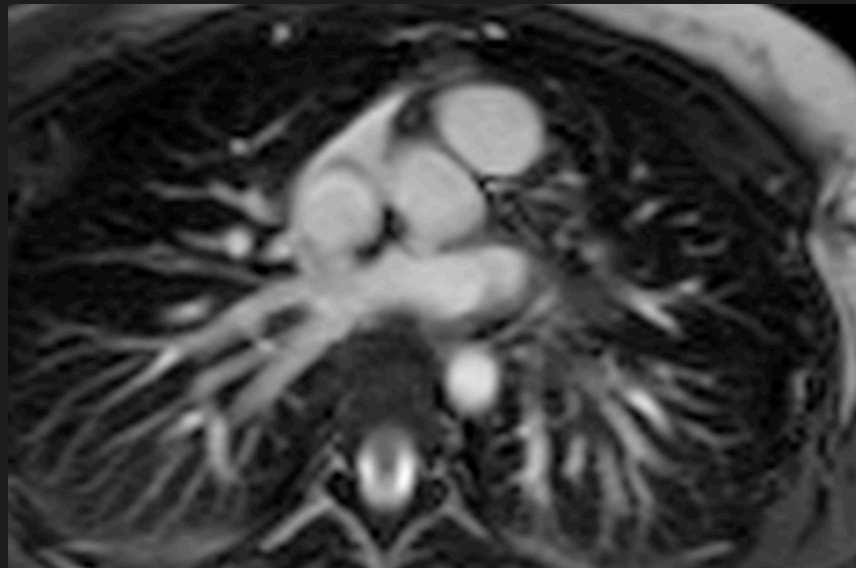
**Qp:Qs > 1**

**RVSV = PASV**

**Look around**



**Sinus Venosus**



**PV blood into RA**

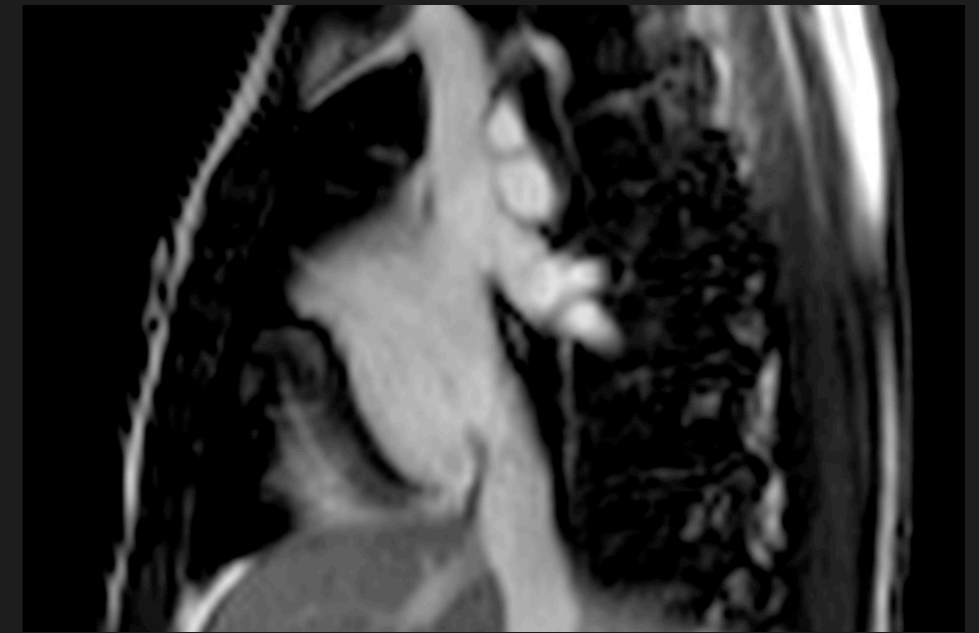
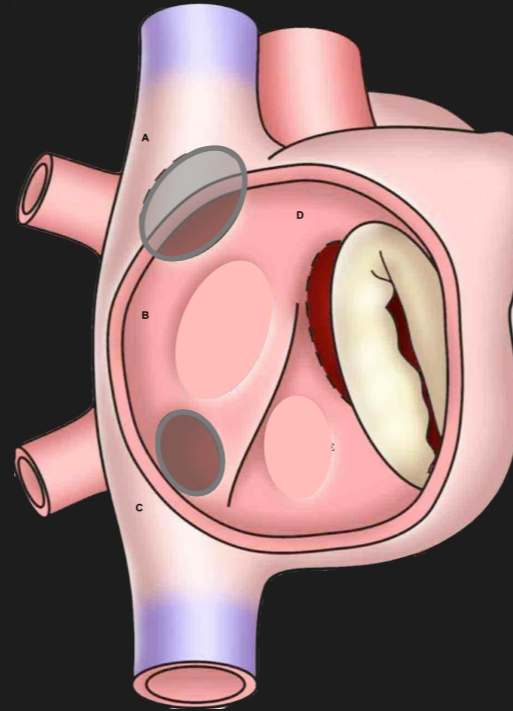
**Like ASD**

**PAPVD**

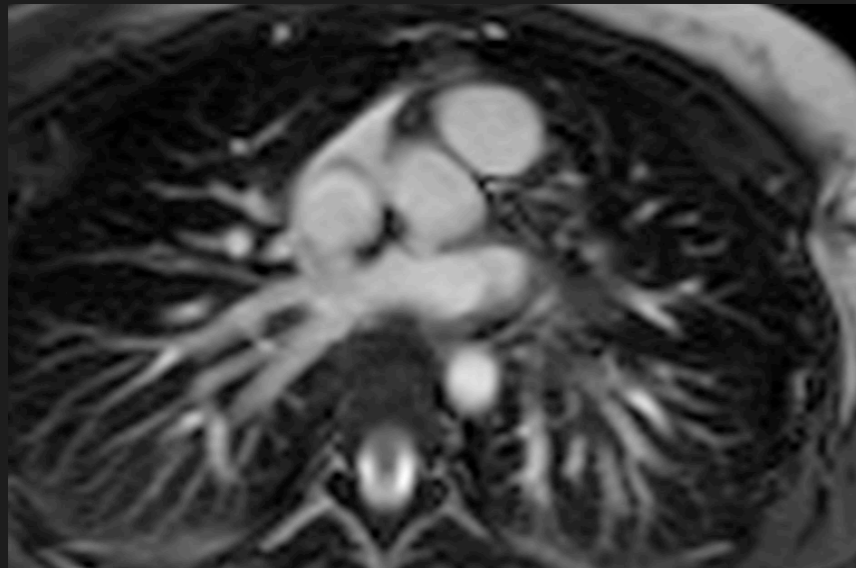
**Qp:Qs > 1**

**RVSV = PASV**

**Look around**



**Sinus Venosus**

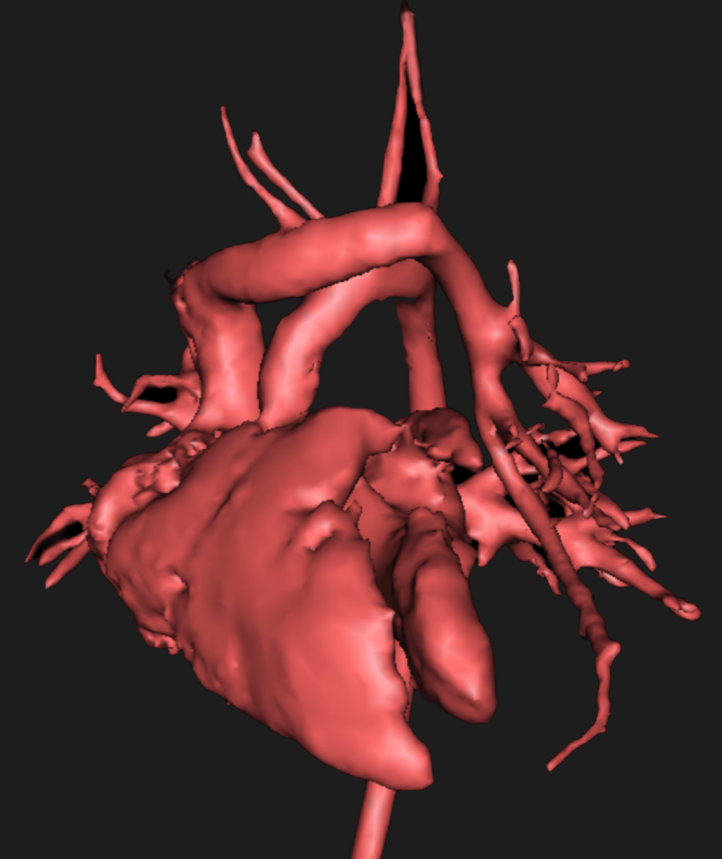

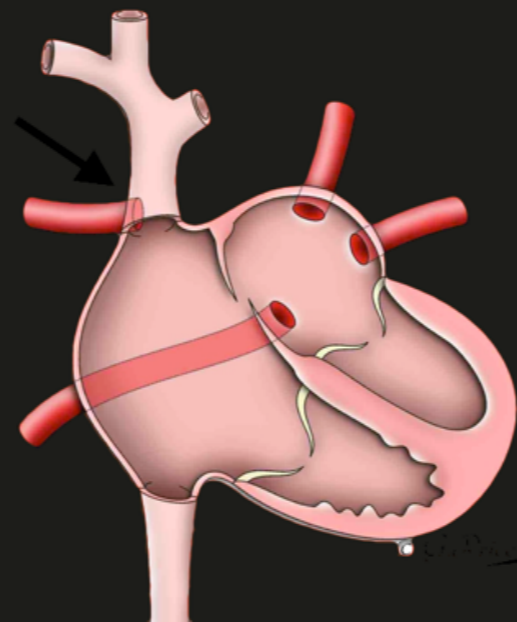
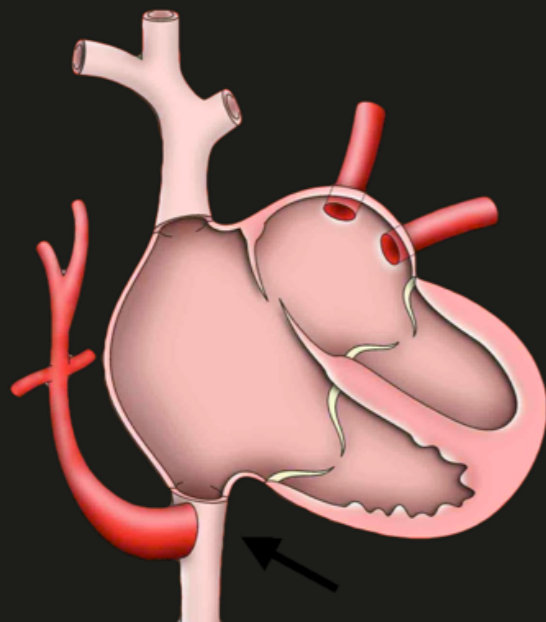
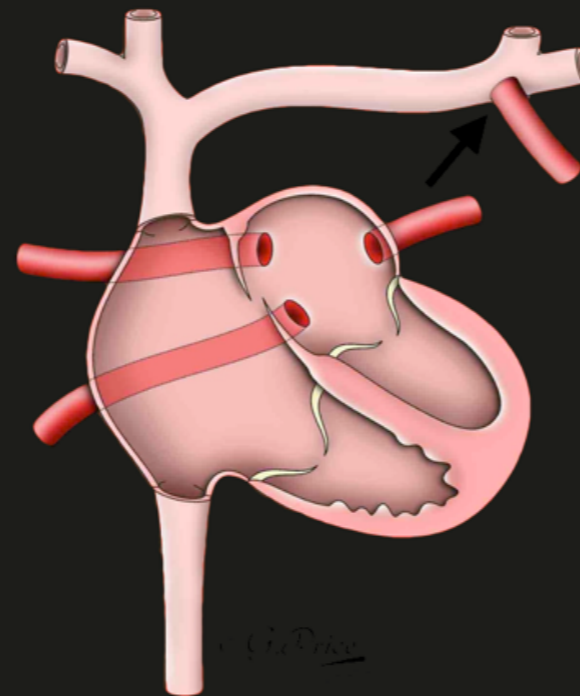
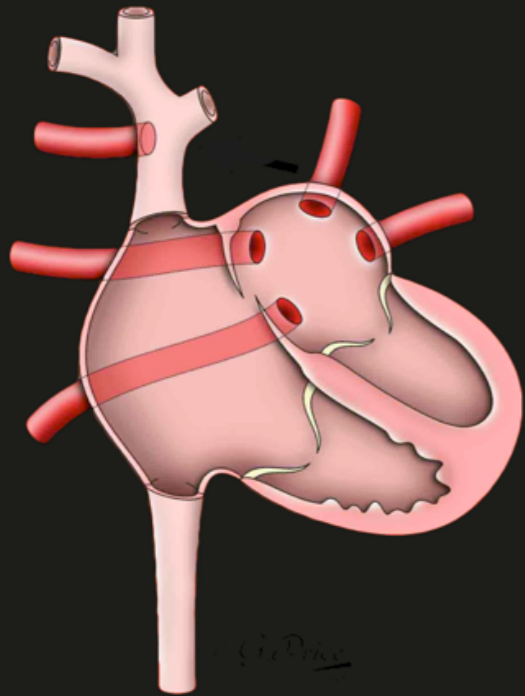
**PV blood into RA**

**Like ASD**

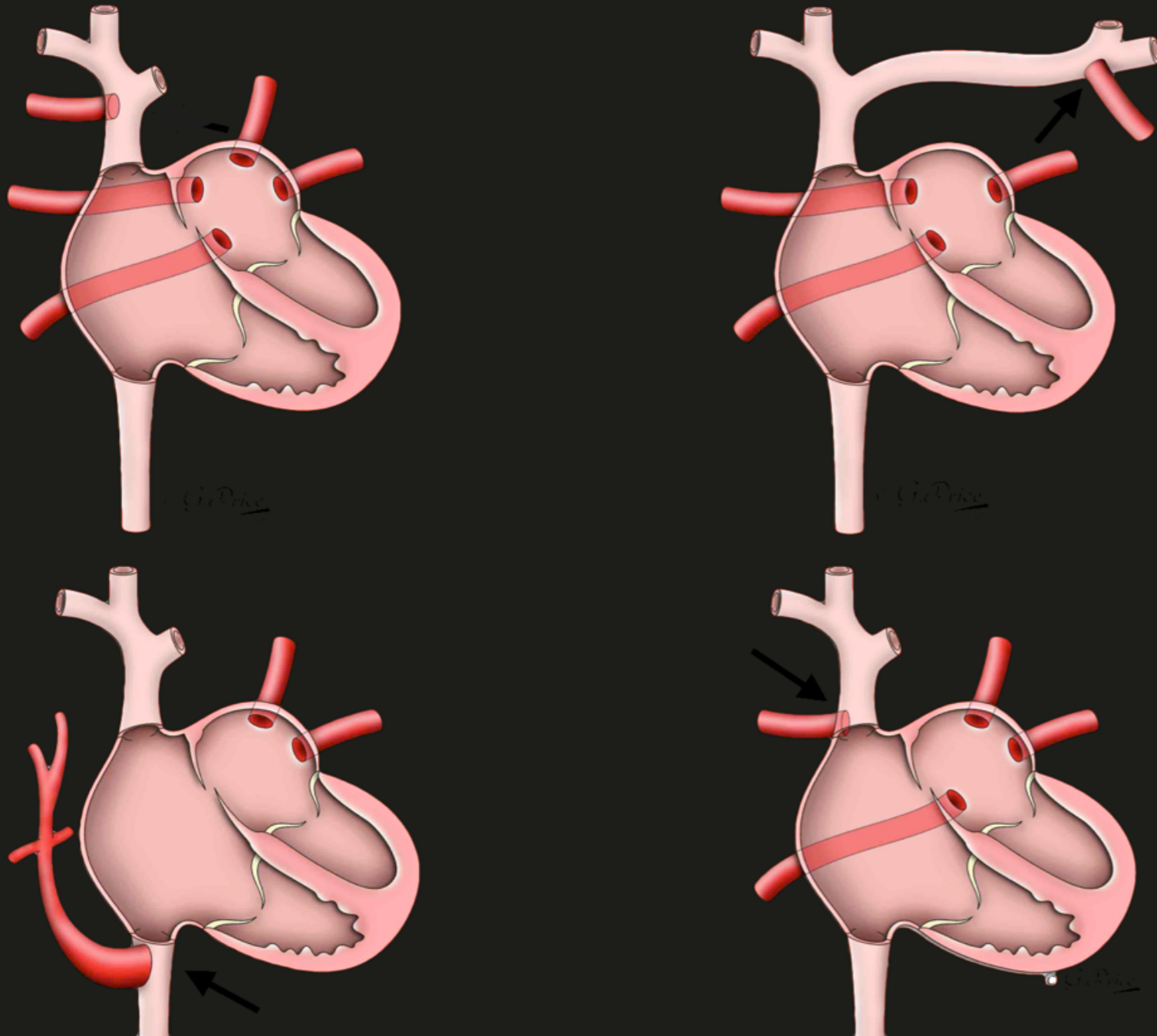
**No need for ASD**

**PAPVD**

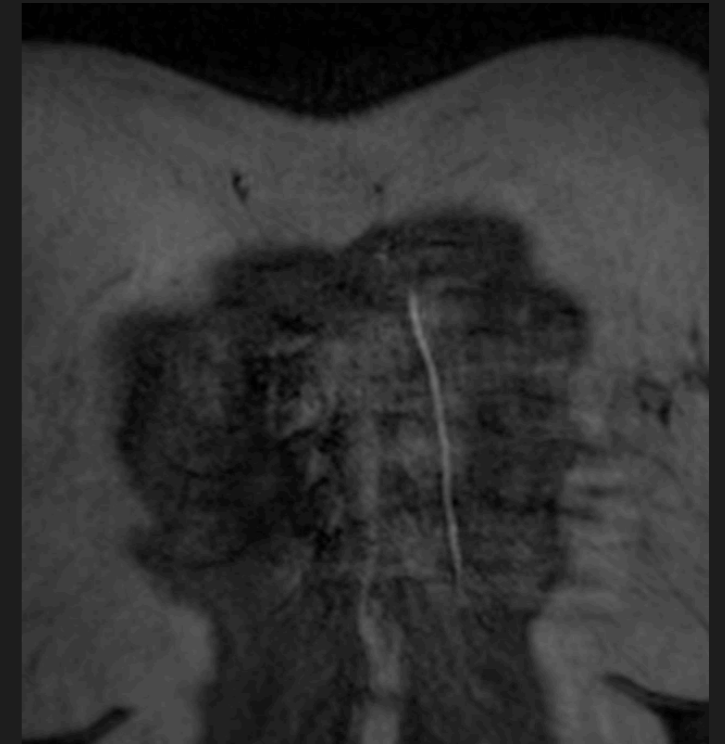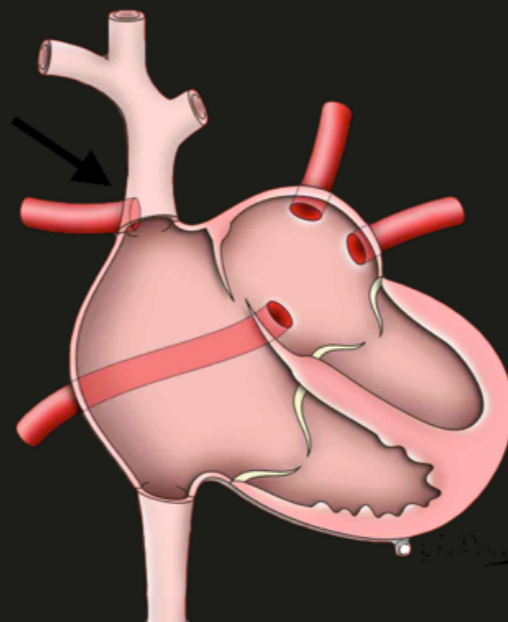
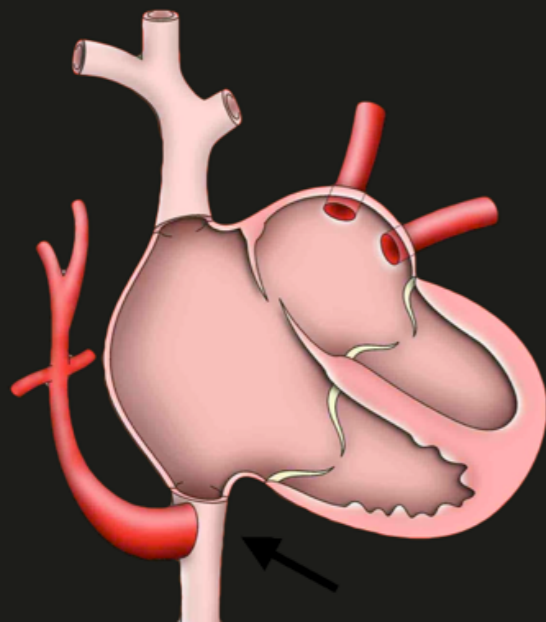
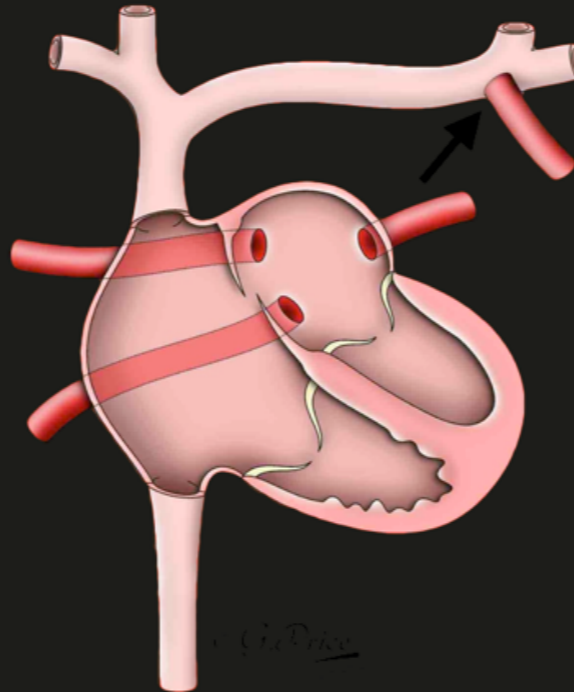
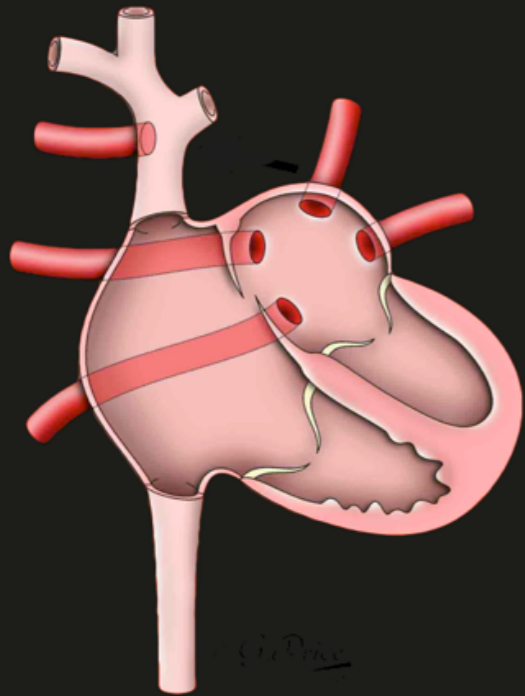




**Multiple variants**

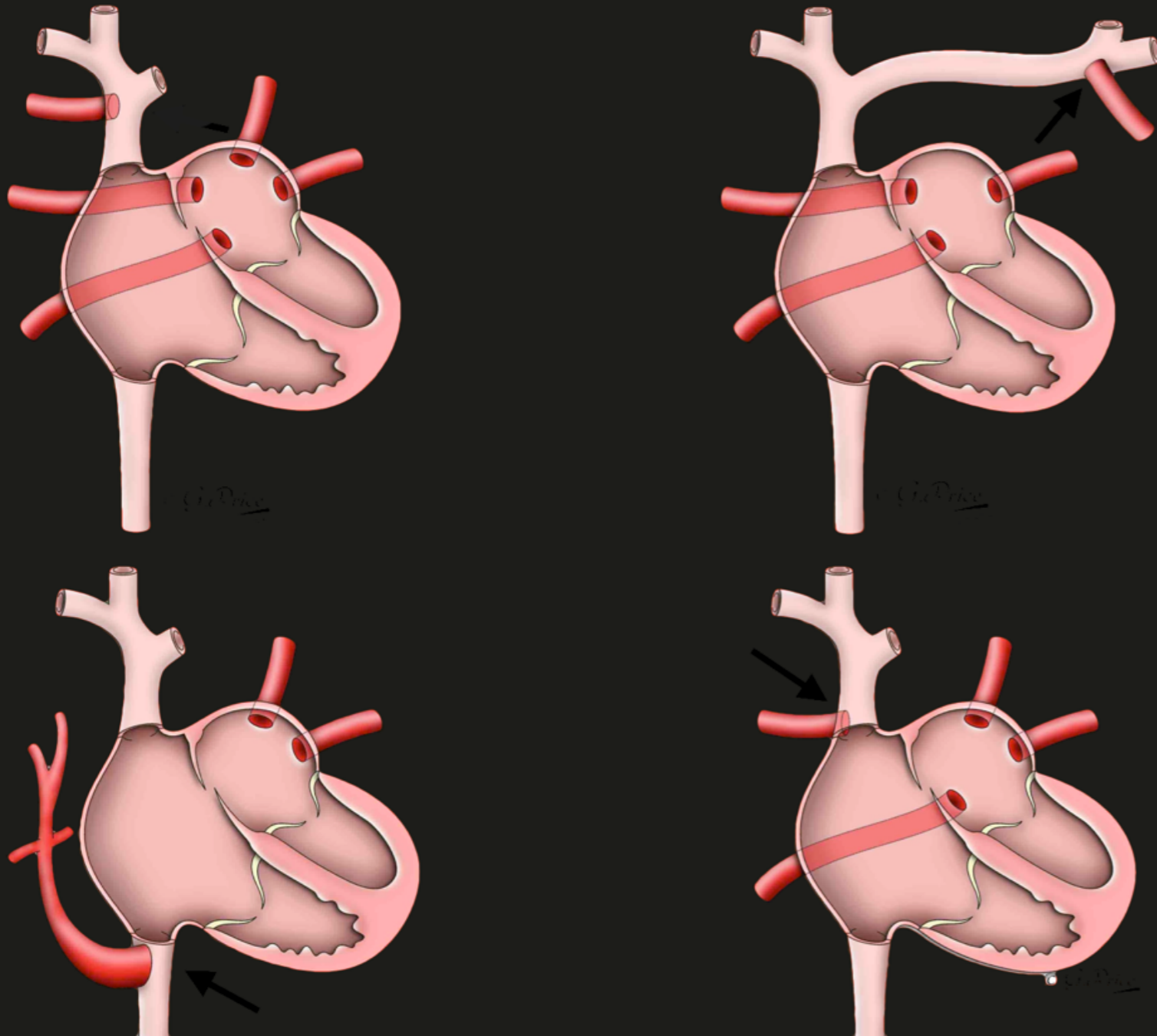


**Multiple variants**

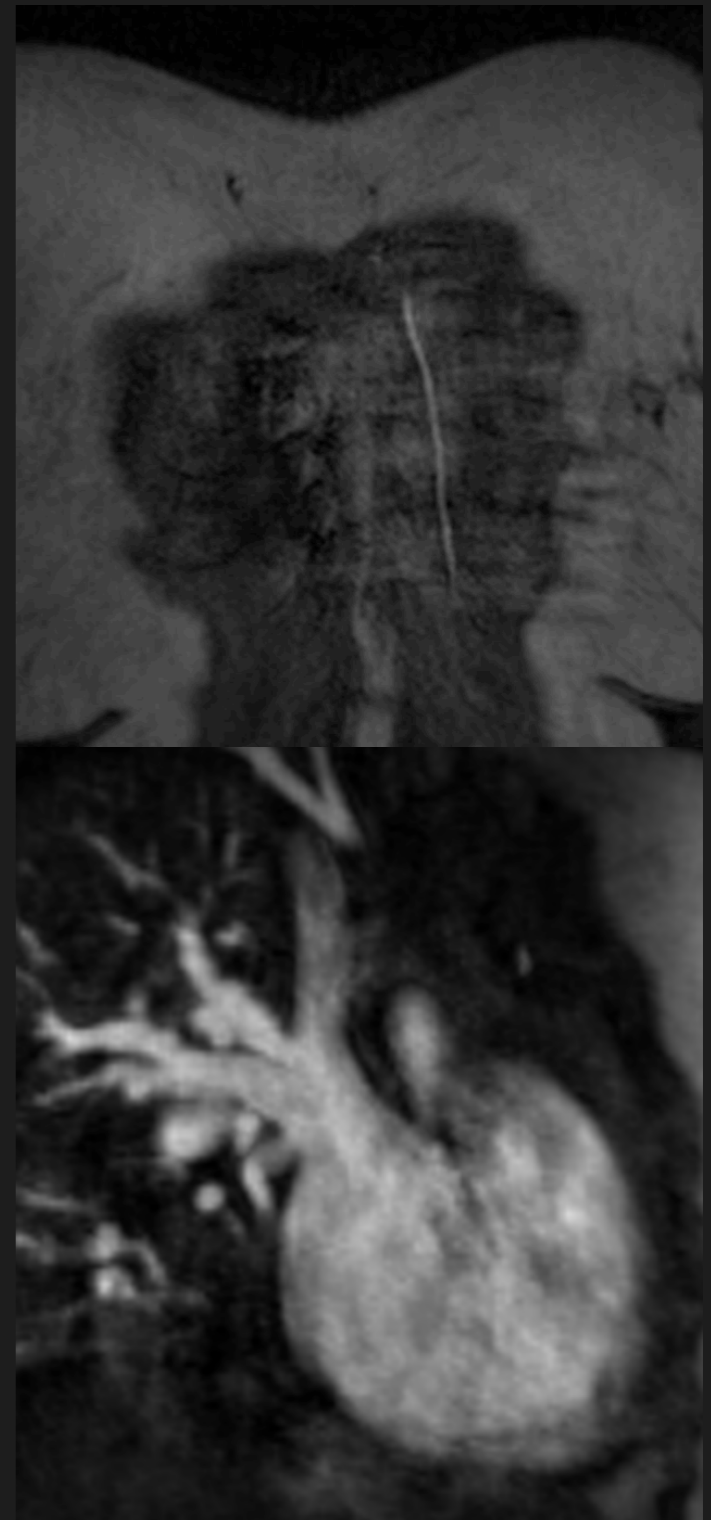


**Multiple variants**

**Angiography**

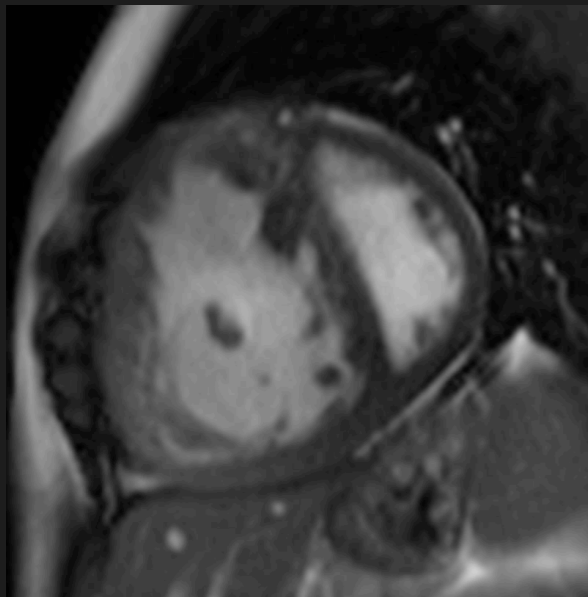
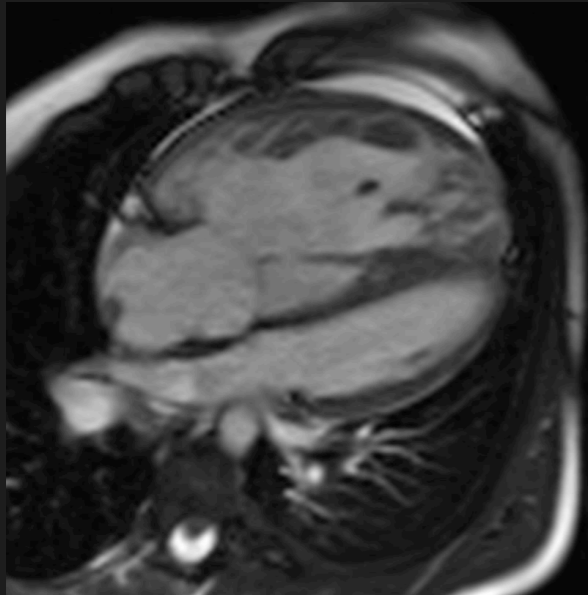


**Multiple variants**

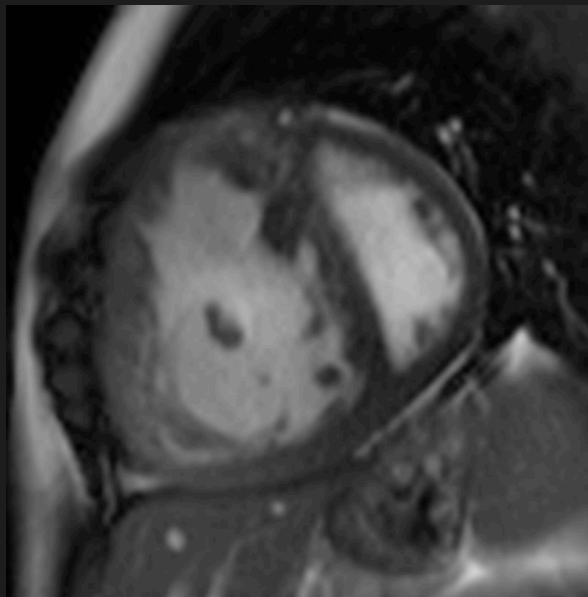
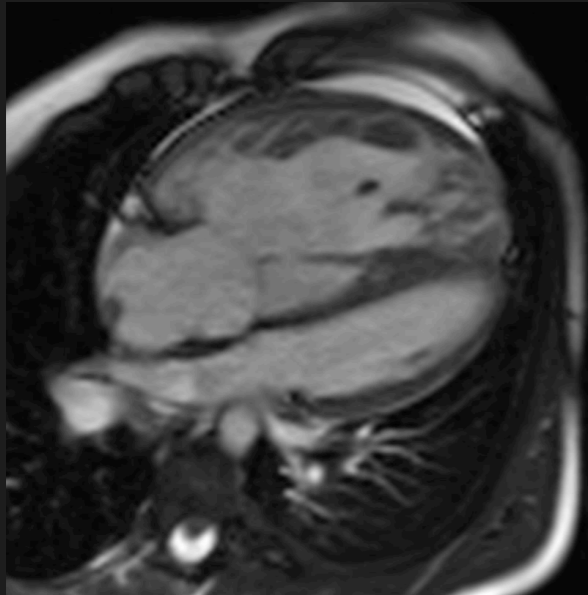


**Angiography**

RVH- ?PH

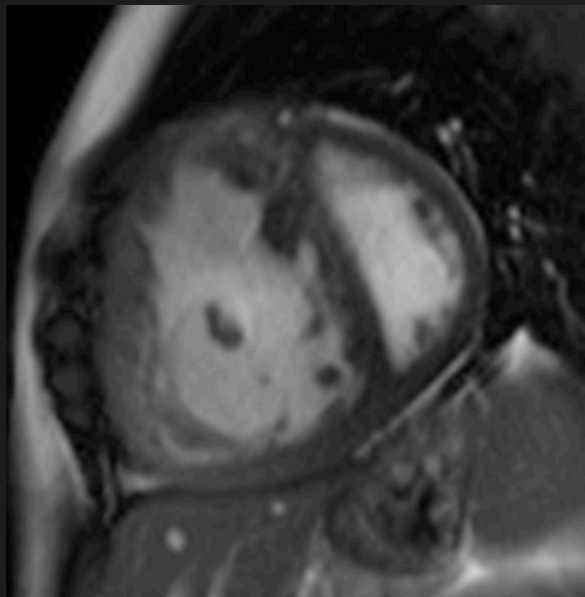
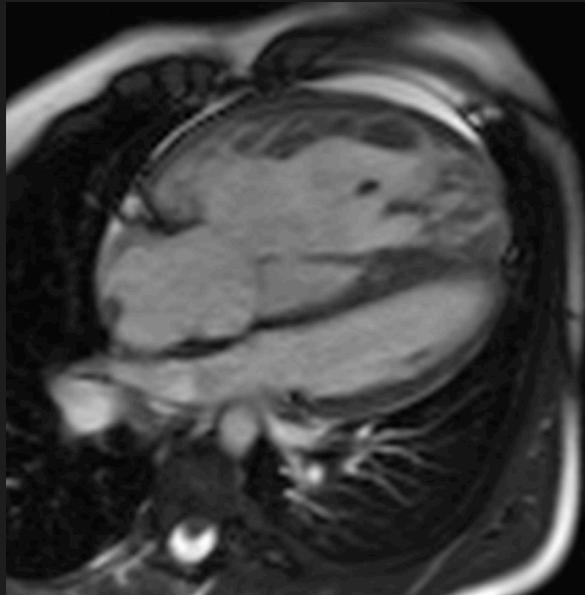


RVH- ?PH



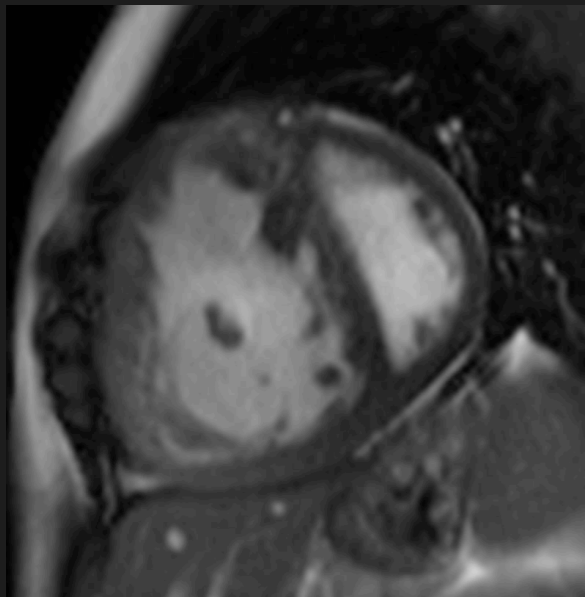
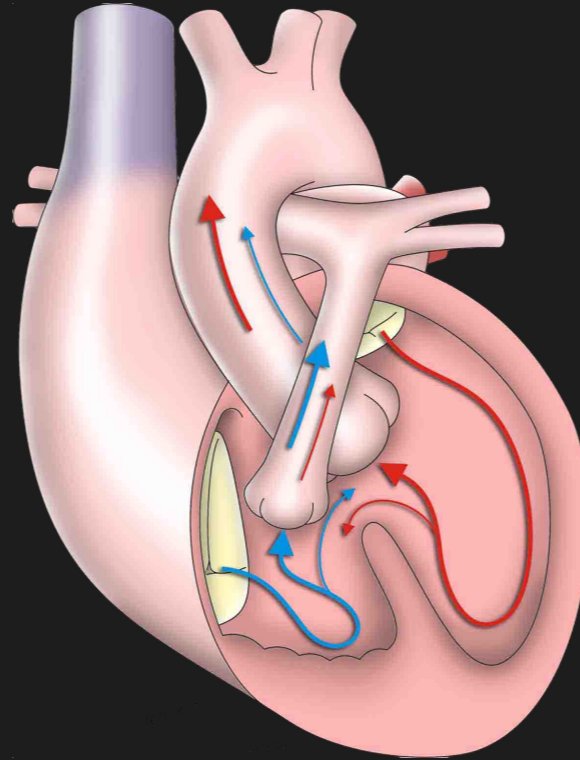
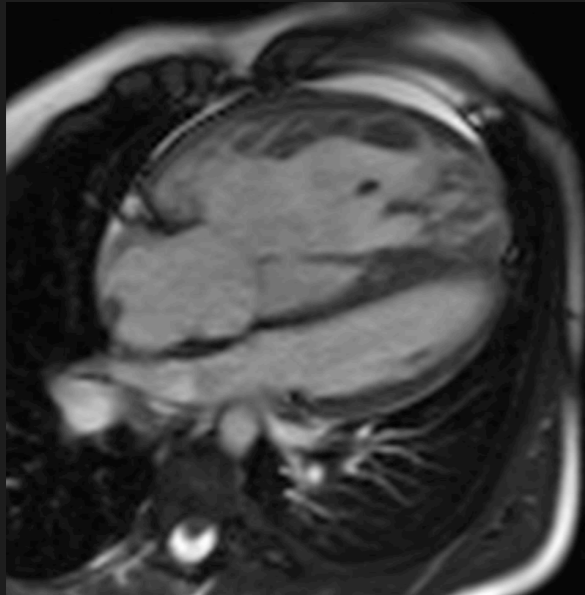


RVH- ?PH



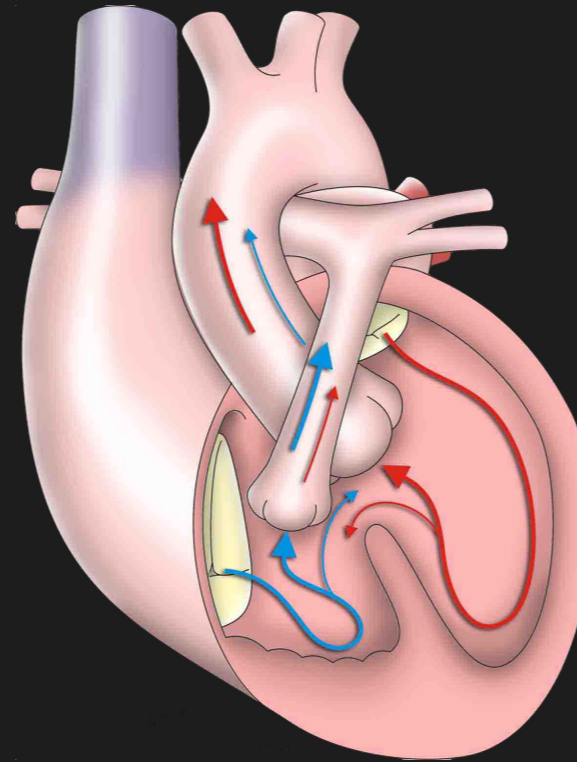
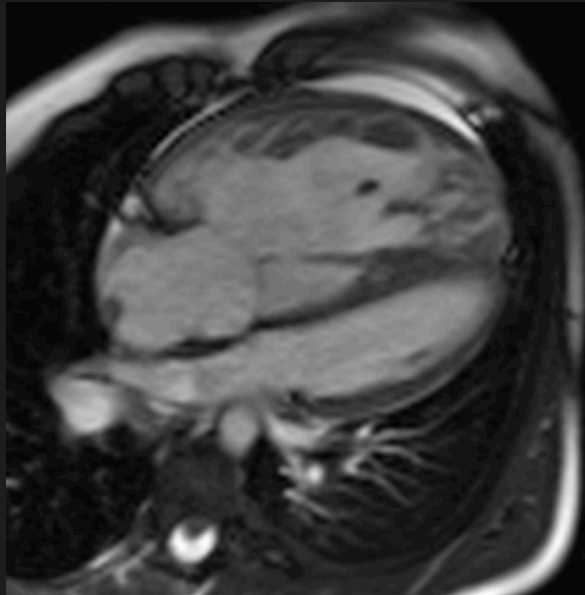
Could it be congenital?

RVH- ?PH



Could it be congenital?

RVH- ?PH



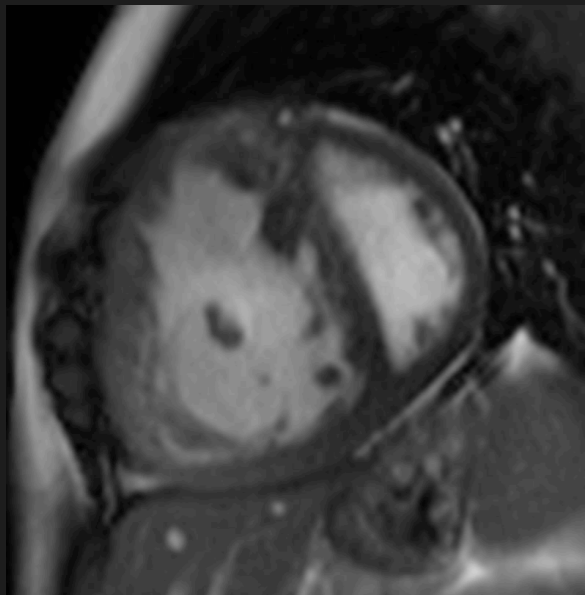
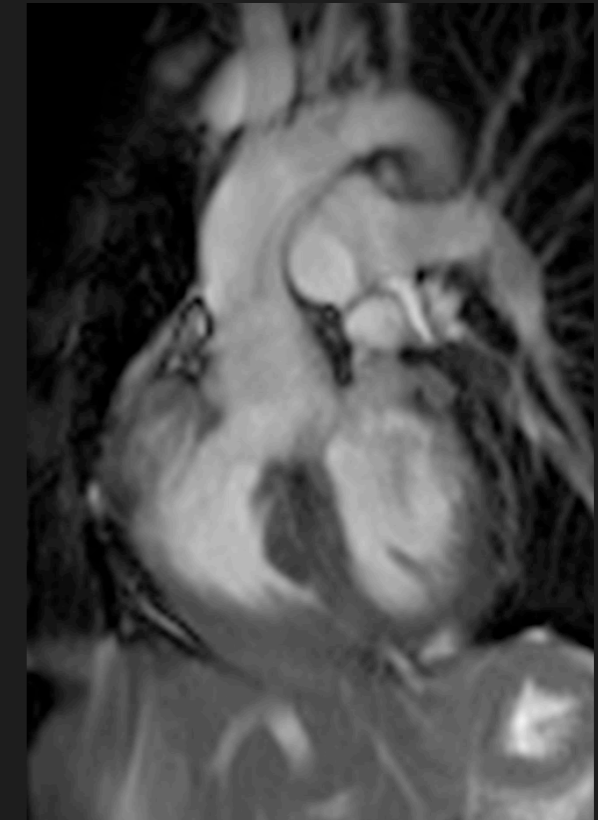
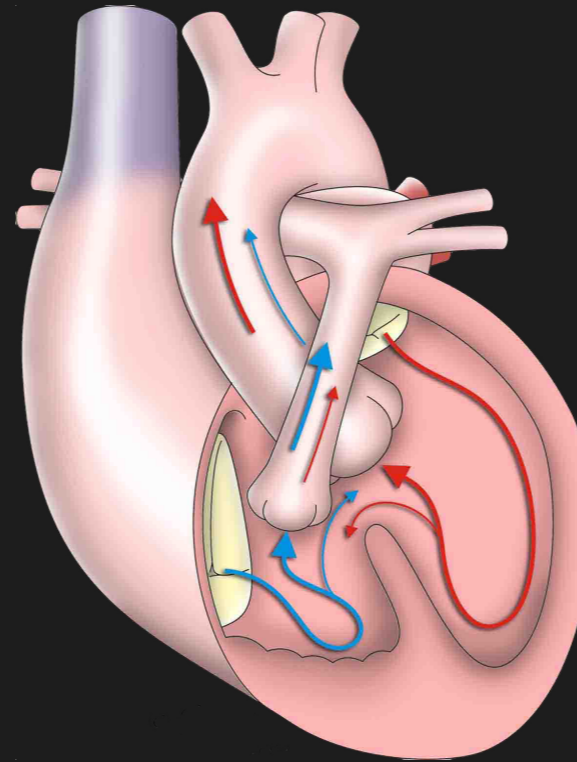
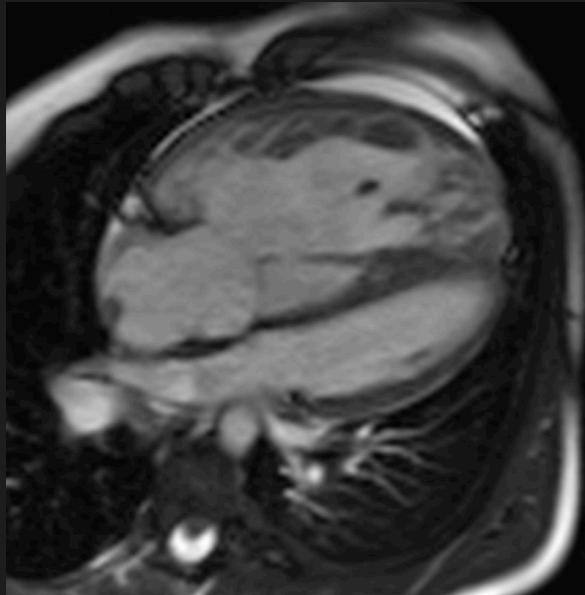
VSD

Overriding Ao

RVOTO, RVH

Could it be congenital?

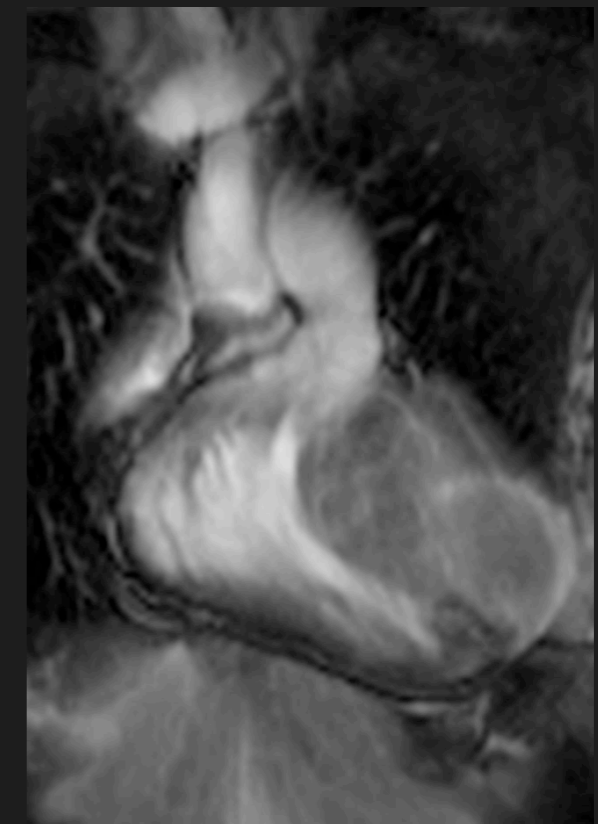
RVH- ?PH



VSD

Overriding Ao

RVOTO, RVH

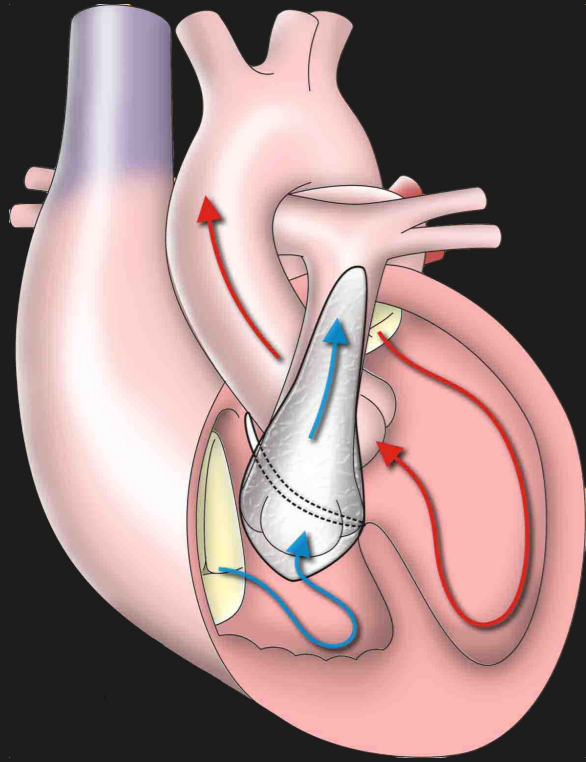


Could it be congenital?

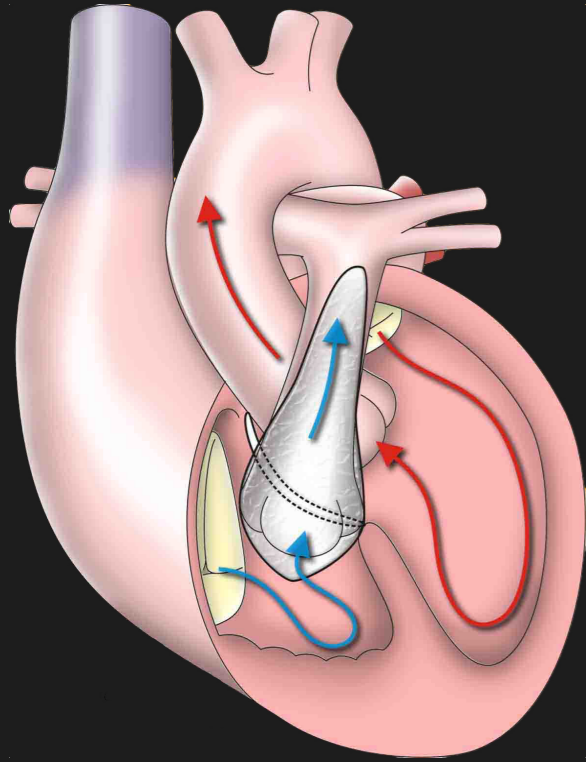




# Tetralogy of Fallot



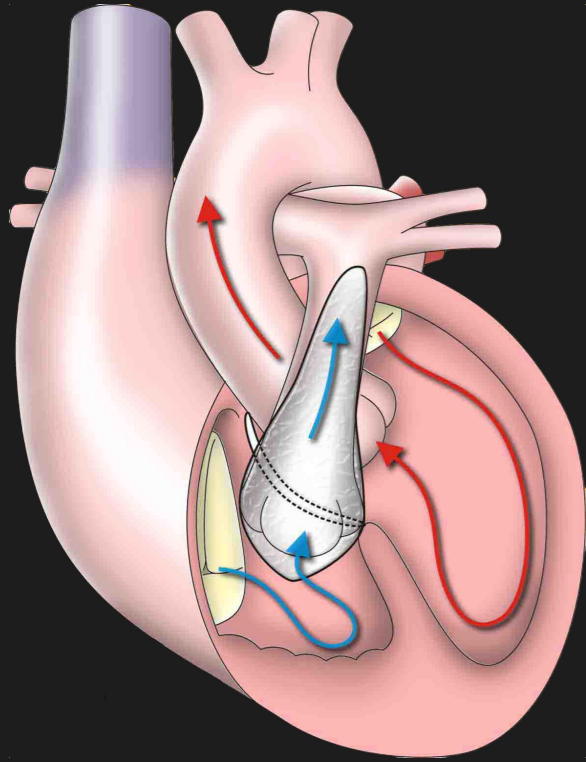
Full repair



Full repair

Trans-annular patch



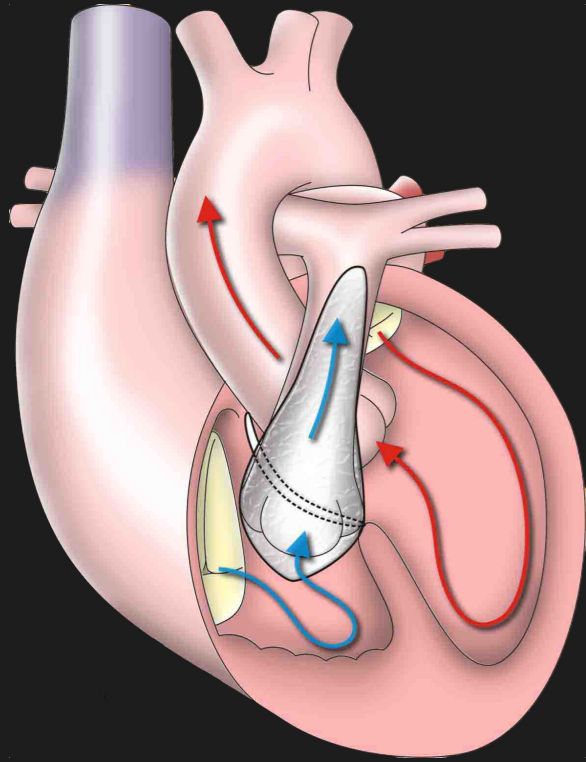


**Full repair**

**Trans-annular patch**

**Close VSD**

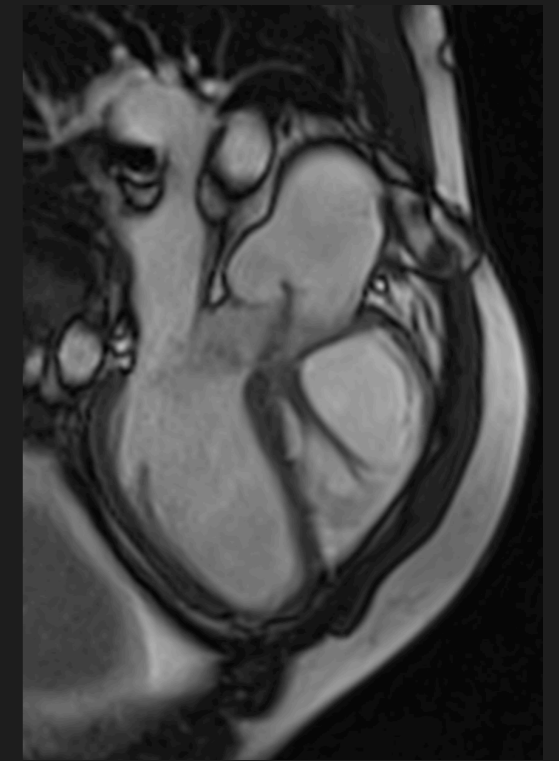
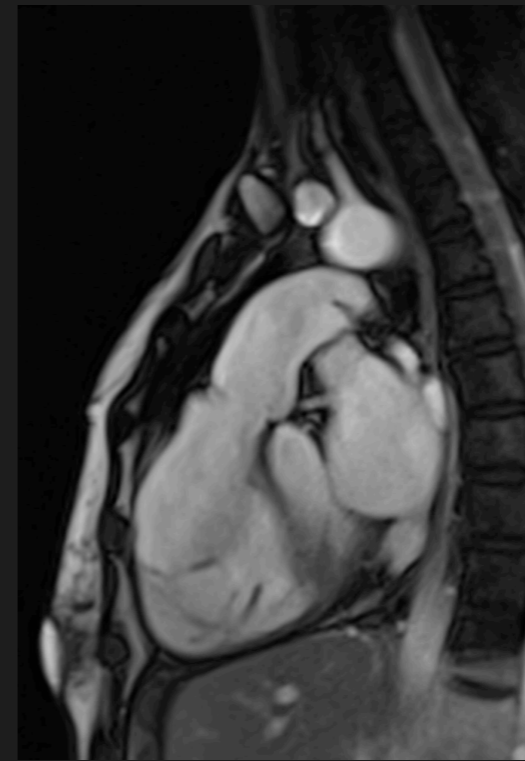
# Tetralogy of Fallot



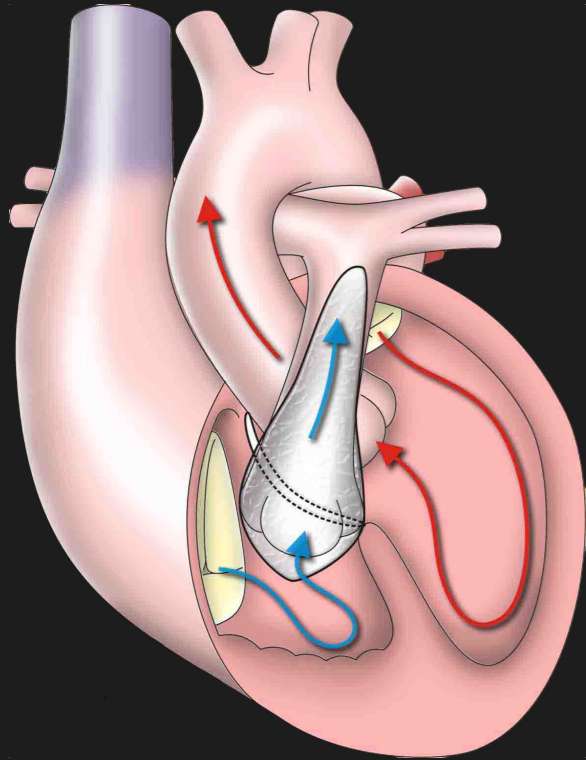
**Full repair**

**Trans-annular patch**

**Close VSD**



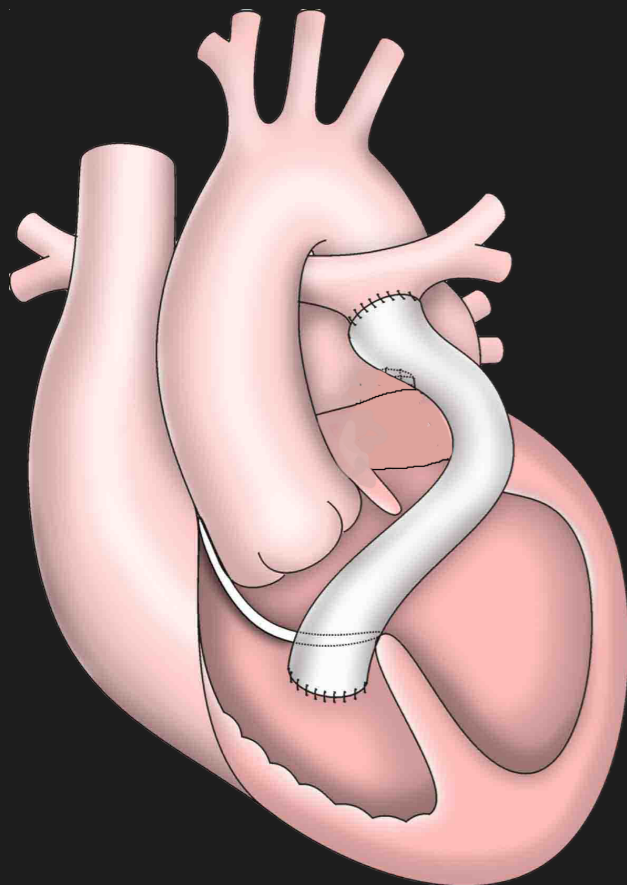
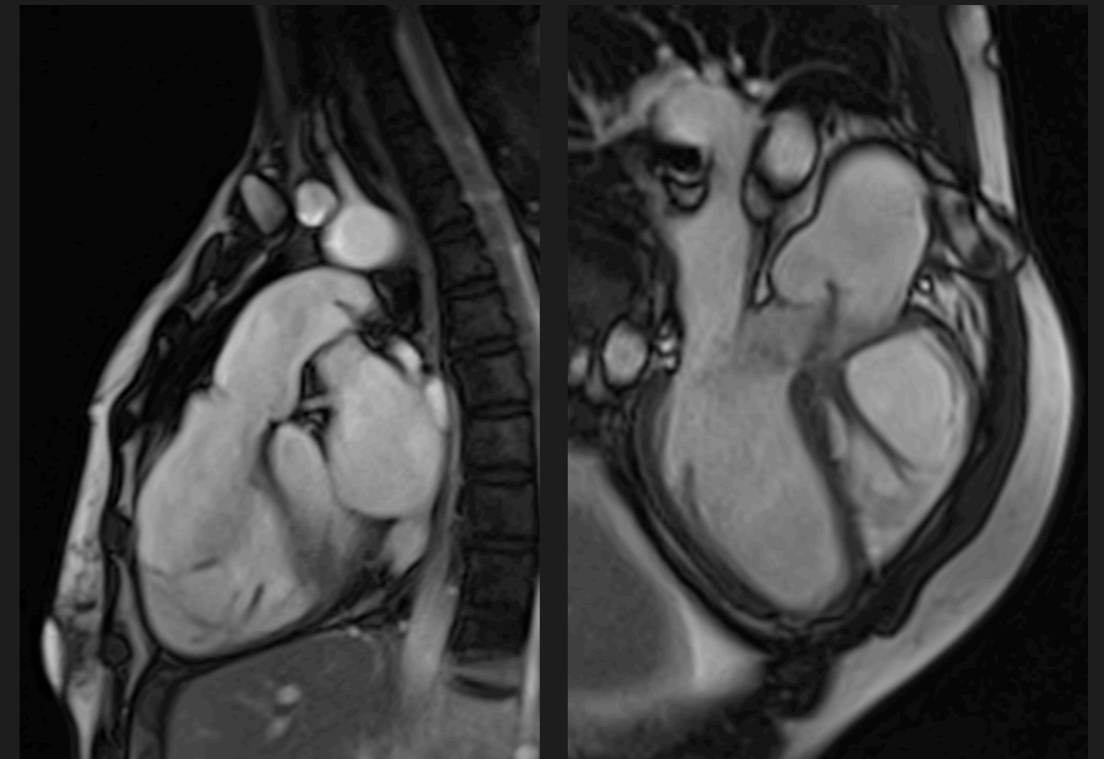
# Tetralogy of Fallot



**Full repair**

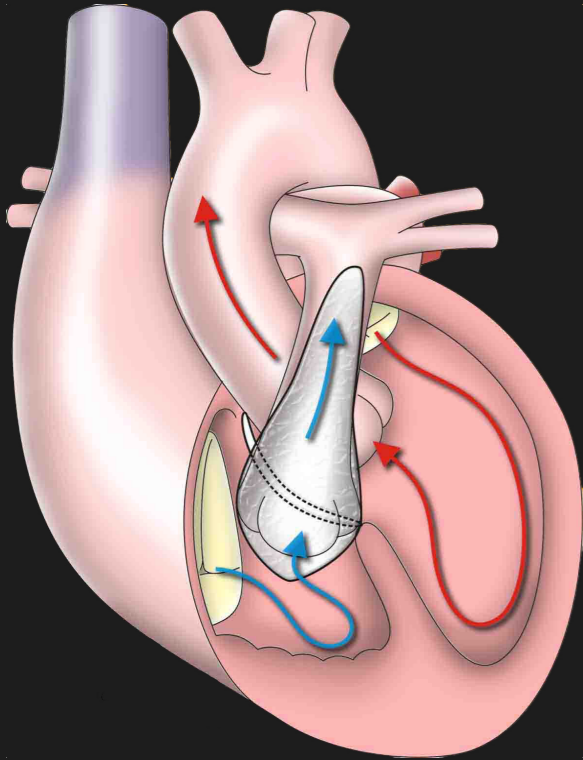
**Trans-annular patch**

**Close VSD**



**Conduit/homograft**

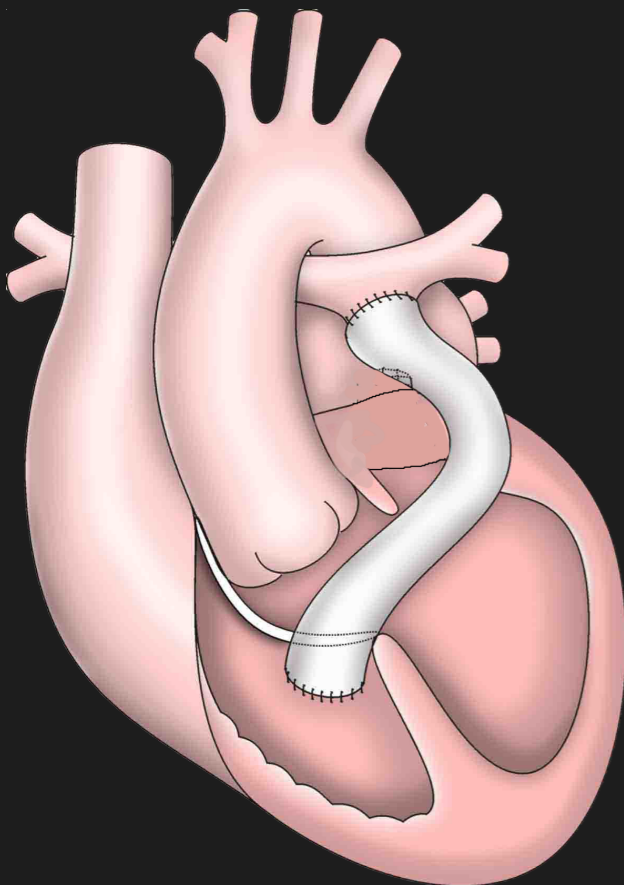
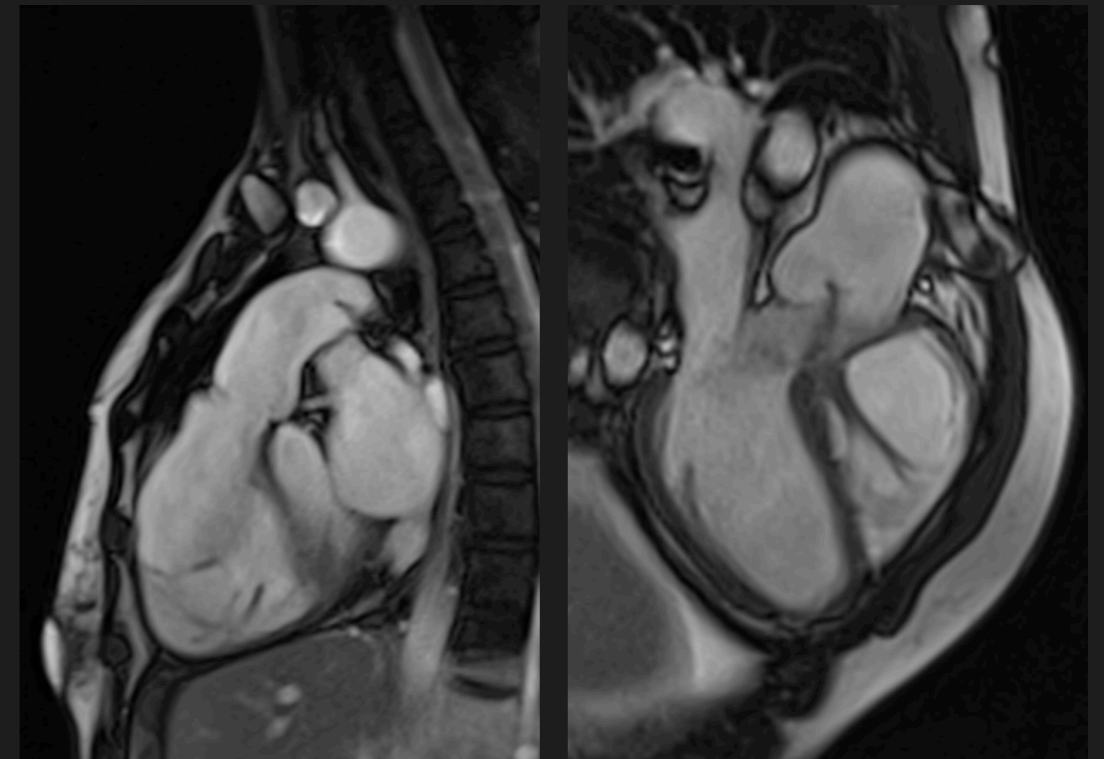
# Tetralogy of Fallot



**Full repair**

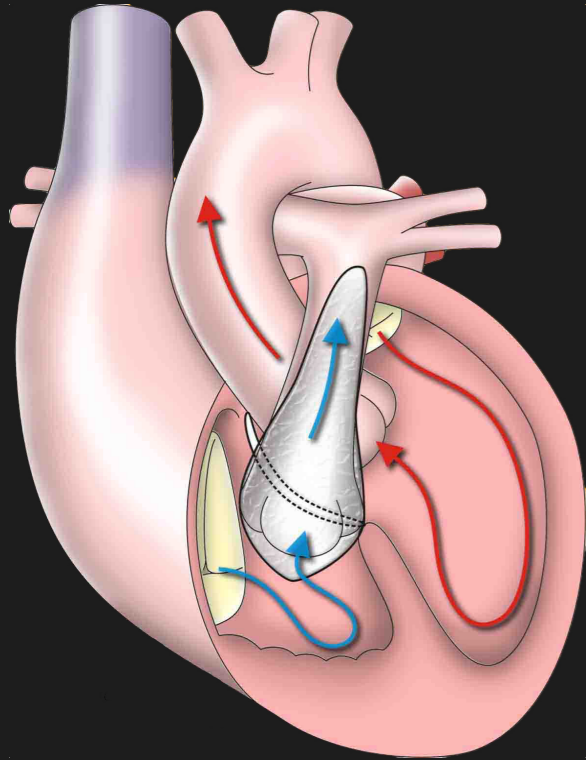
**Trans-annular patch**

**Close VSD**



**Conduit/homograft**

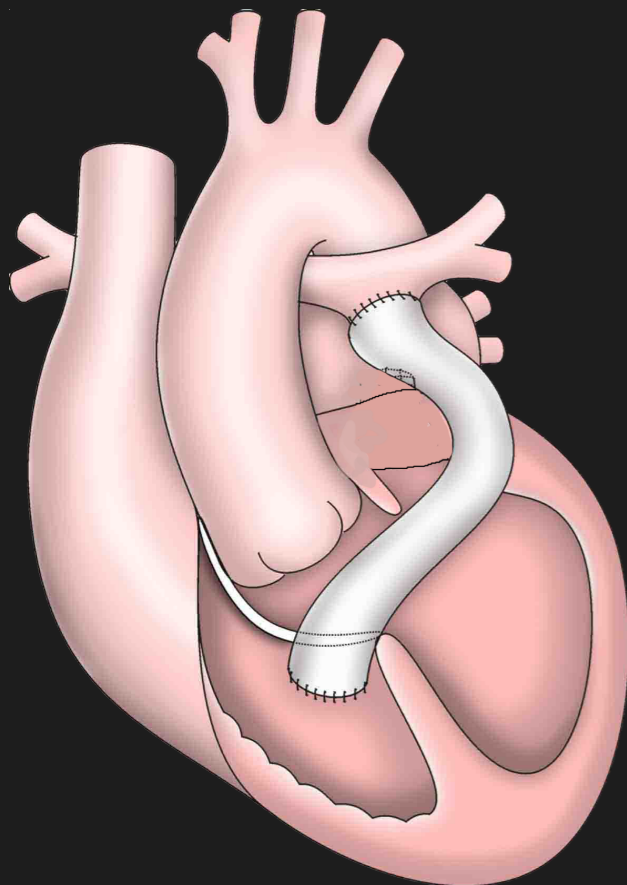
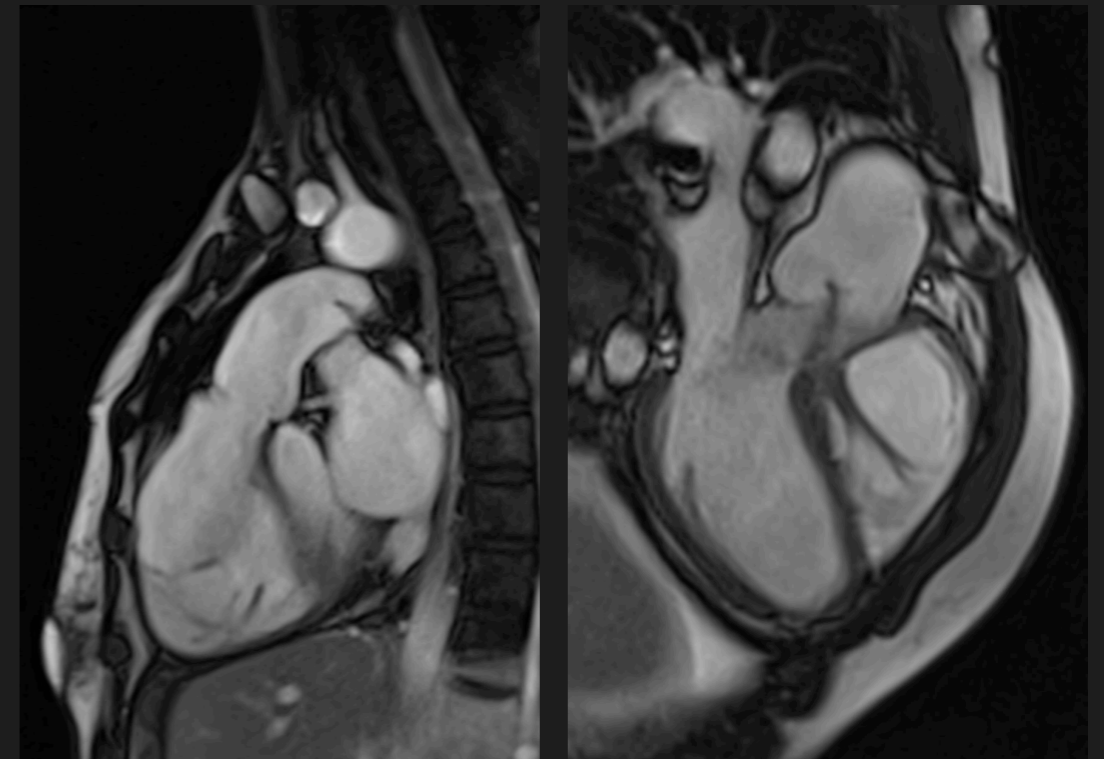
**VSD repair**



**Full repair**

**Trans-annular patch**

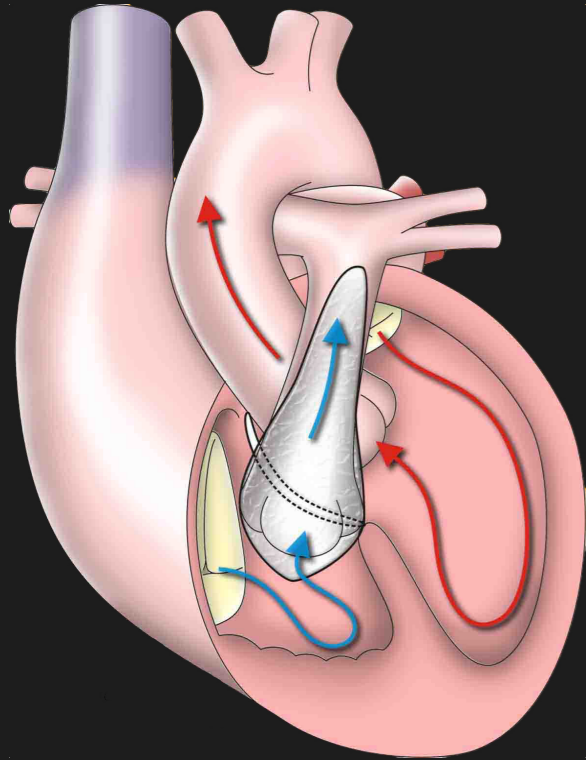
**Close VSD**



**Conduit/homograft**

**VSD repair**

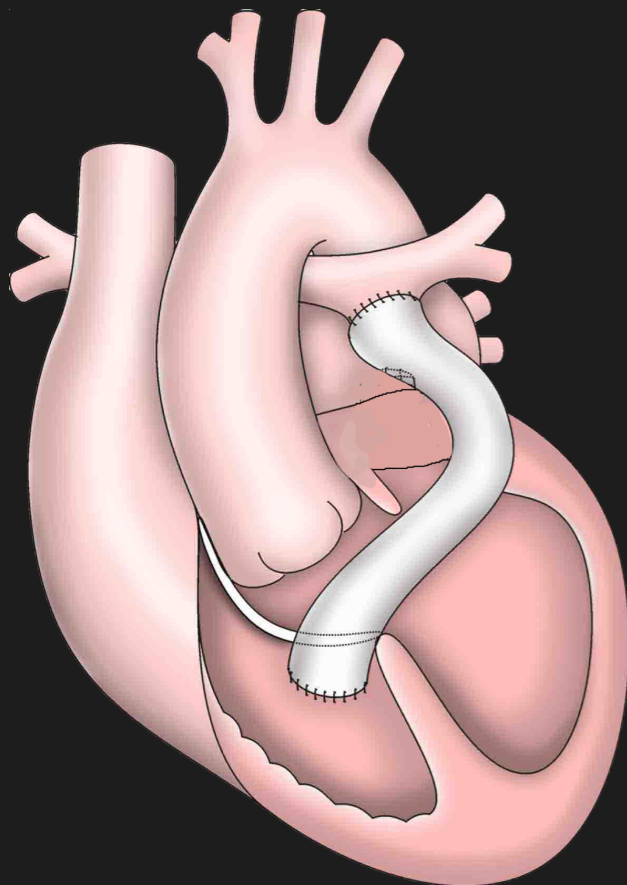
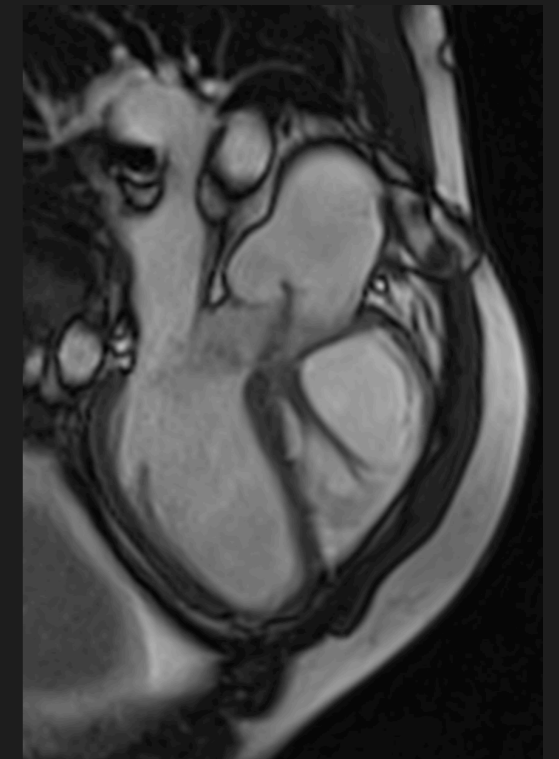
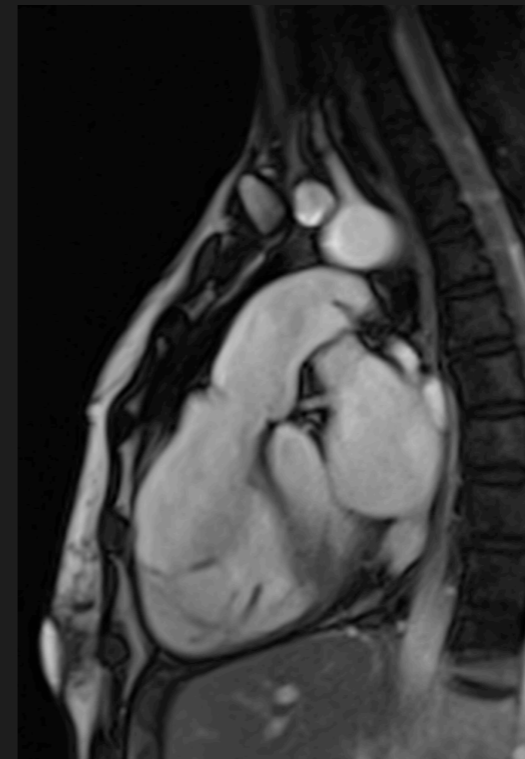
**Pul. Stenosis**



**Full repair**

**Trans-annular patch**

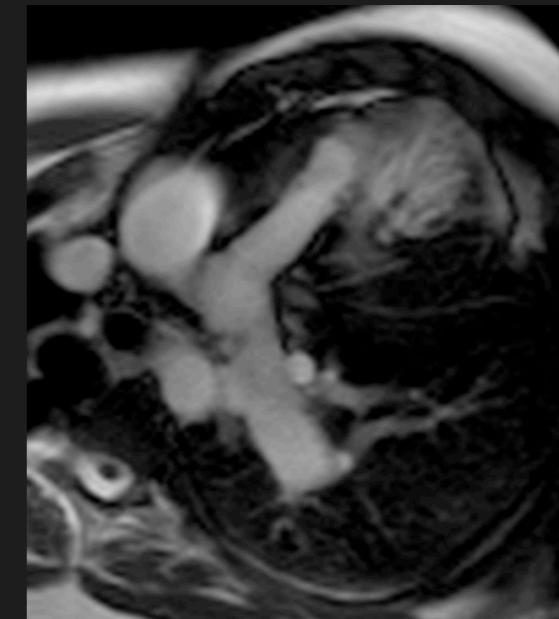
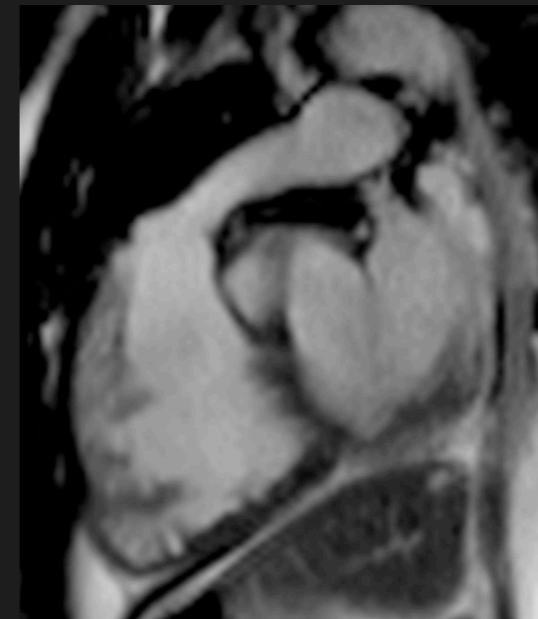
**Close VSD**



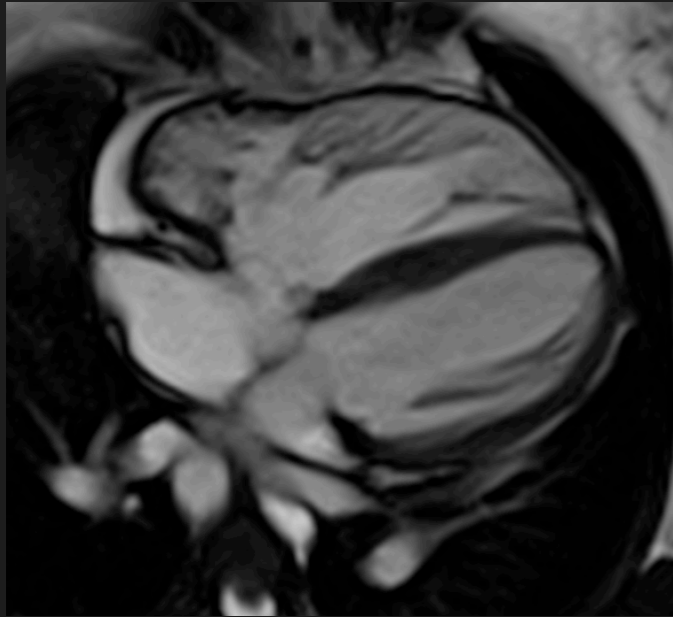
**Conduit/homograft**

**VSD repair**

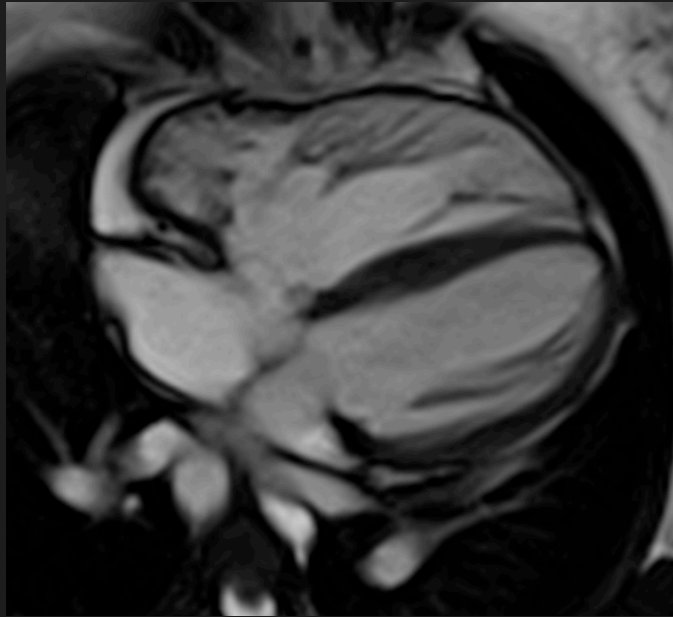
**Pul. Stenosis**



# Tetralogy of Fallot

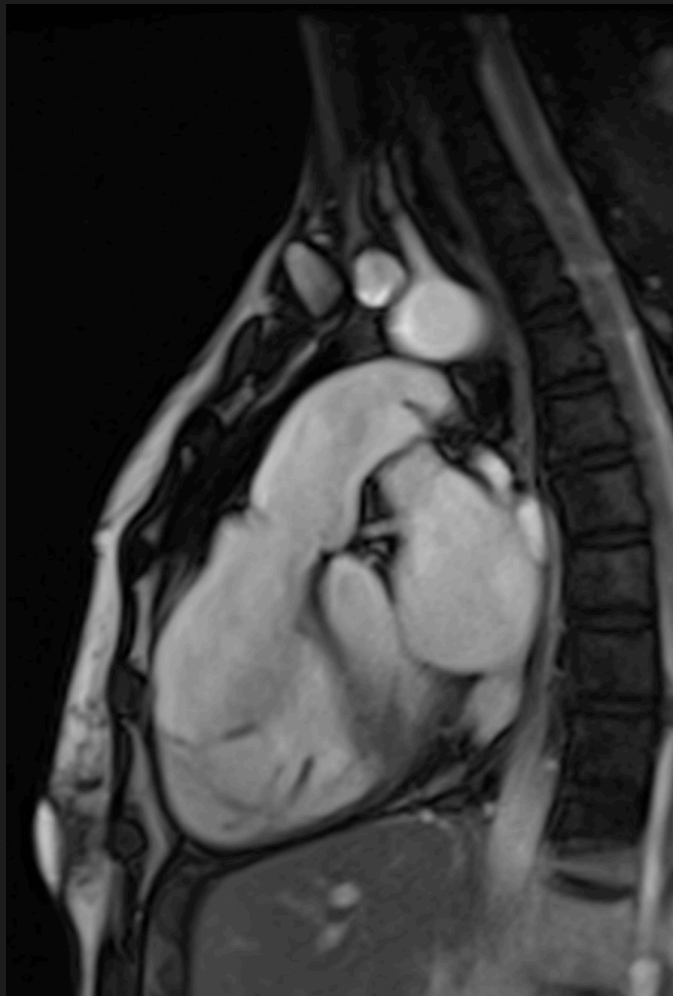
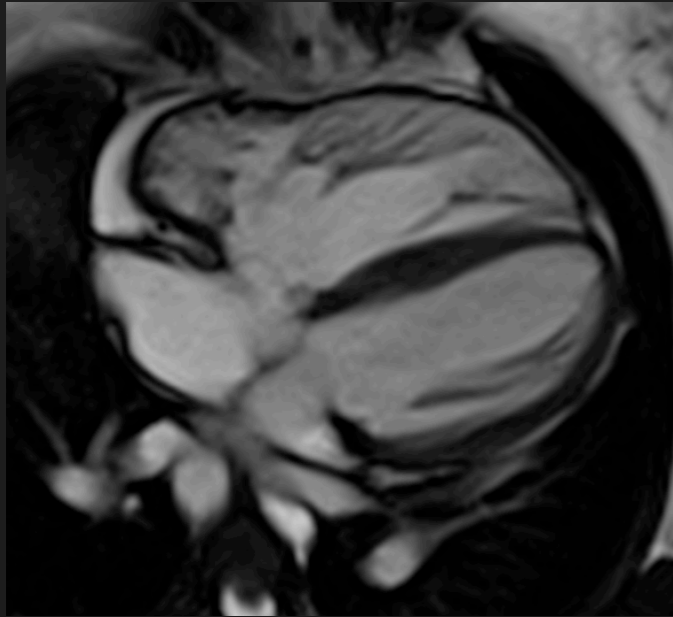


# Tetralogy of Fallot

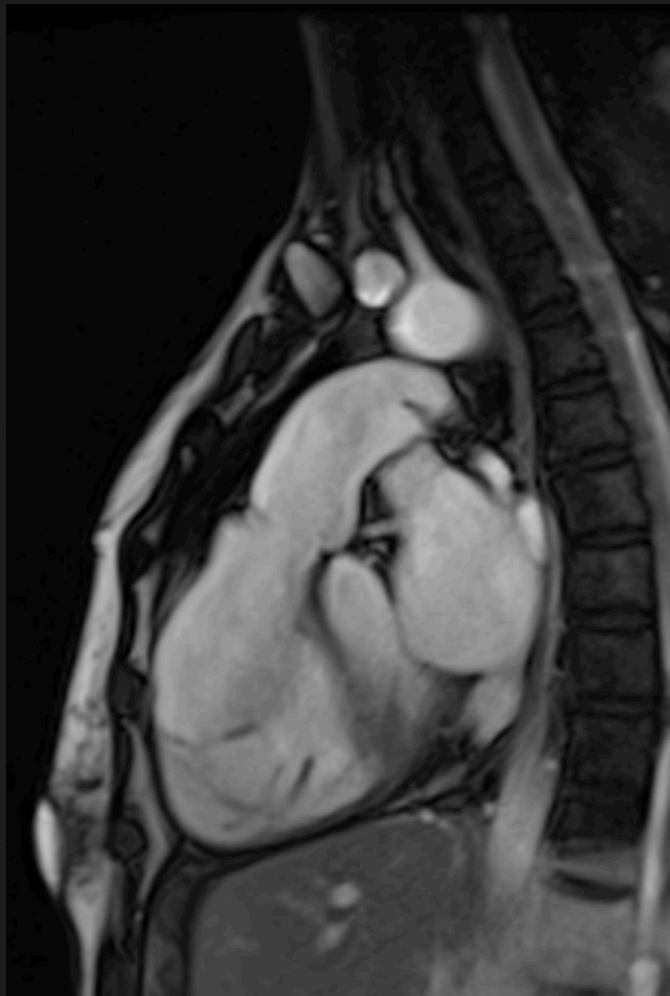
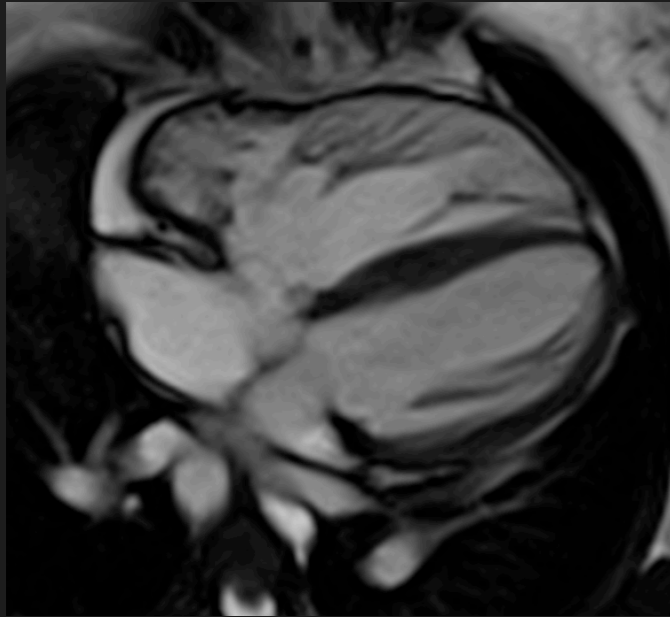




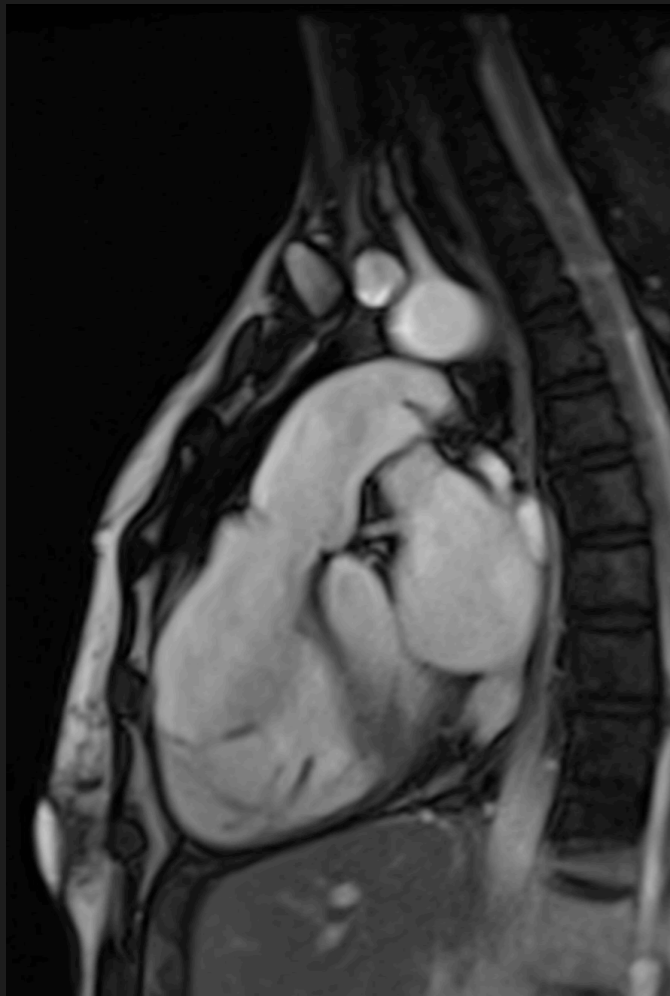
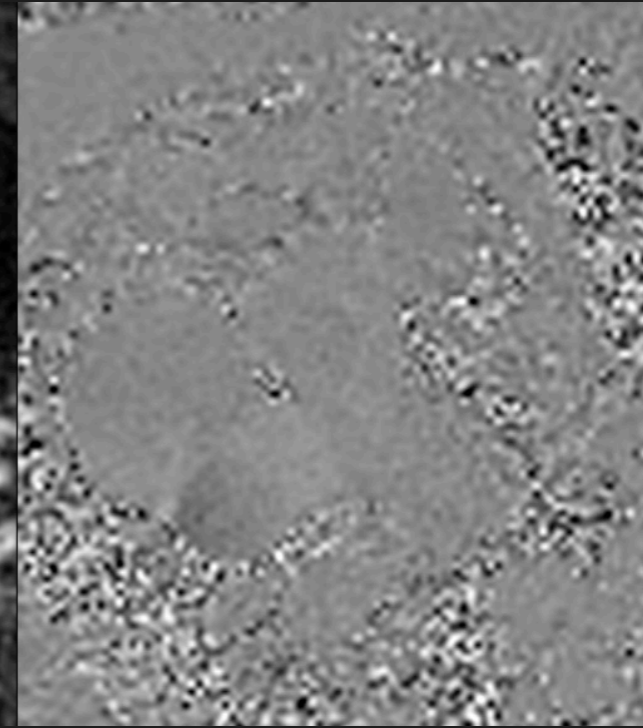
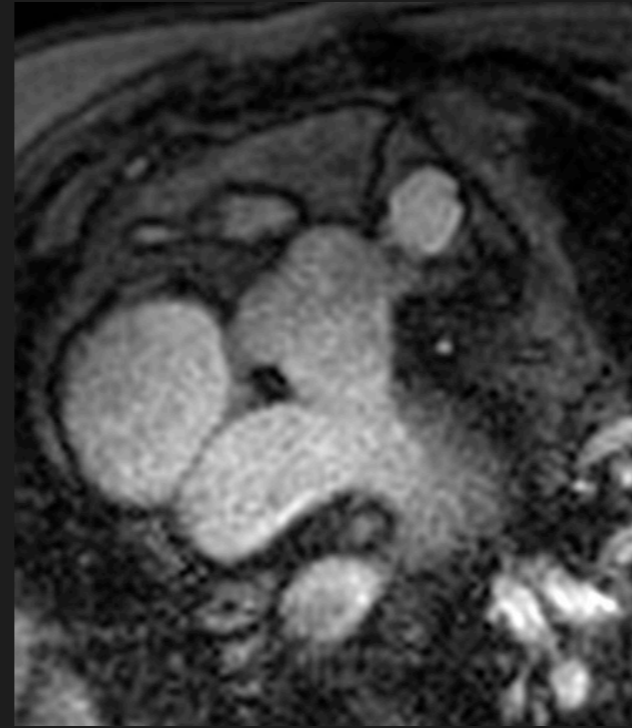
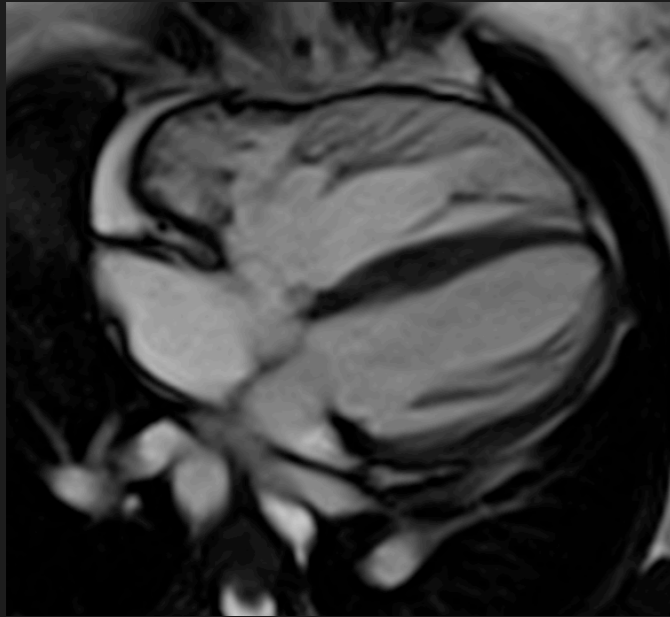
# Tetralogy of Fallot




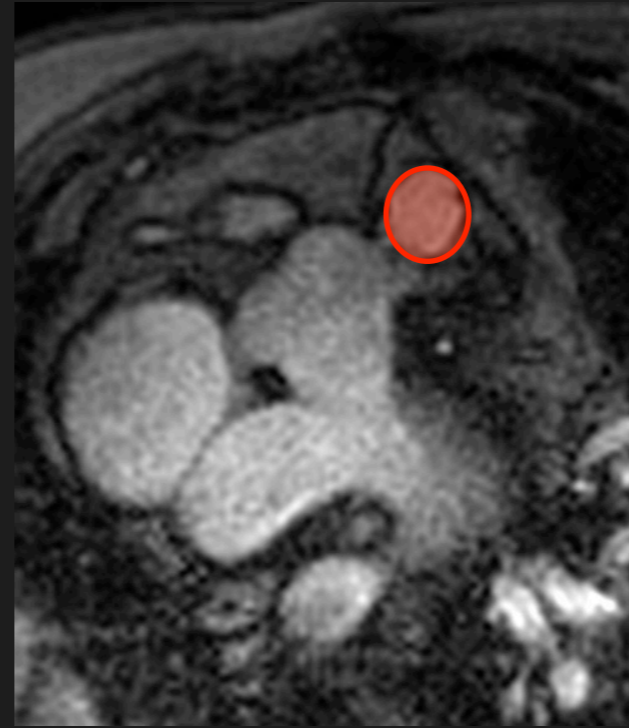
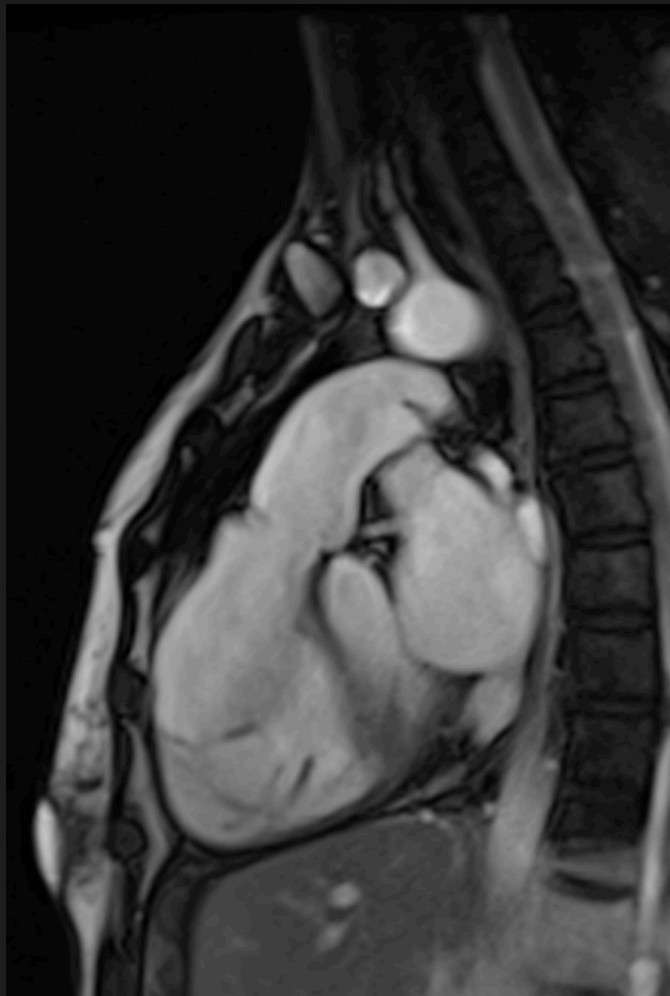
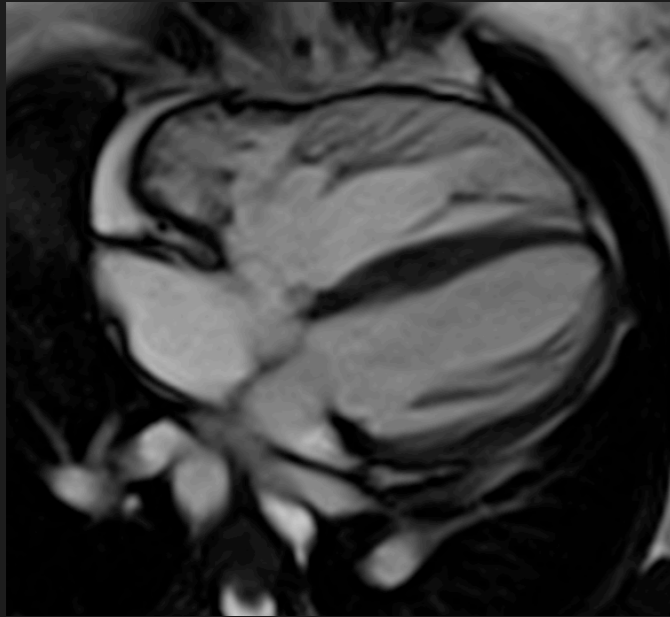
## Quantify Regurgitation



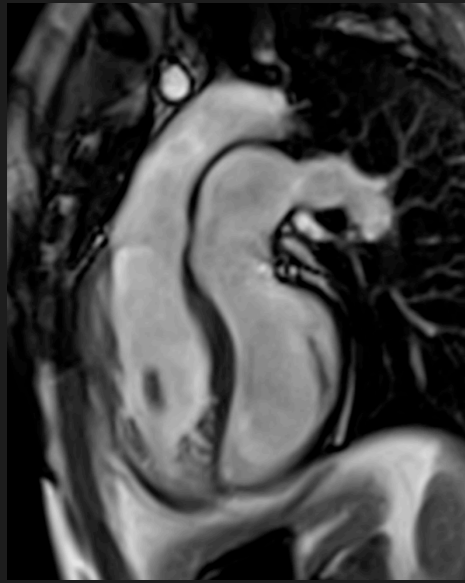
## Quantify Regurgitation



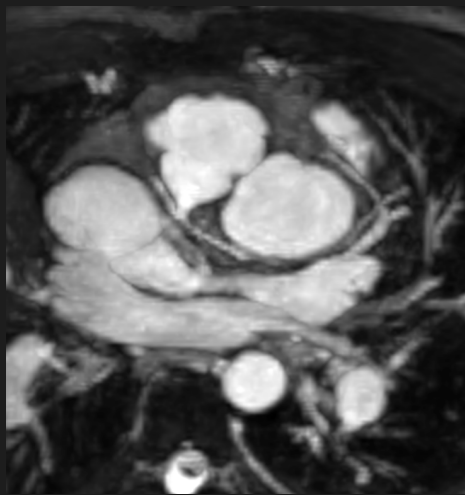
## Quantify Regurgitation



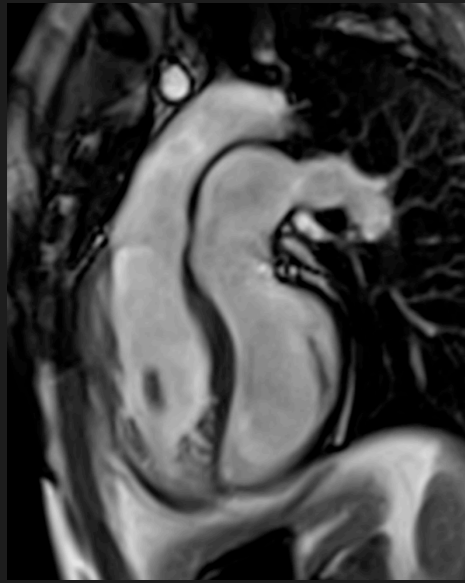
PA FV	75 mls
PA RV	25 mls
Ao FV	50 mls
PA RF	33%



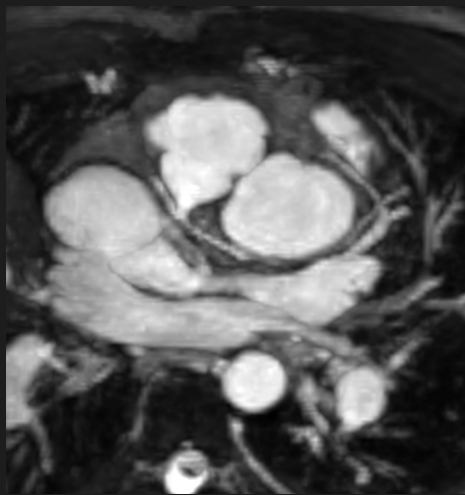
**VA discordance**



**Cor. off Ao**

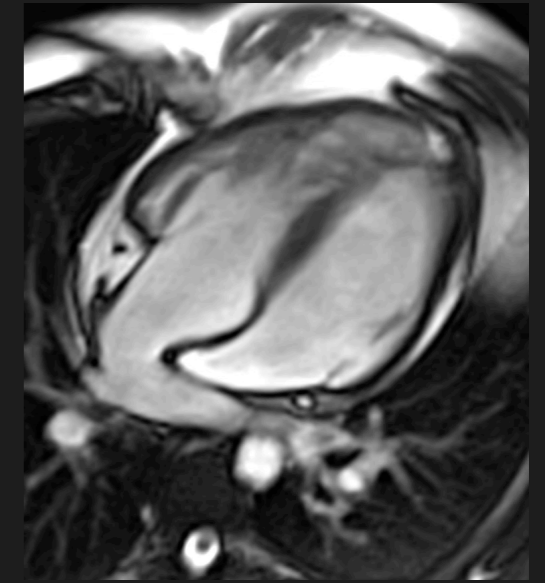
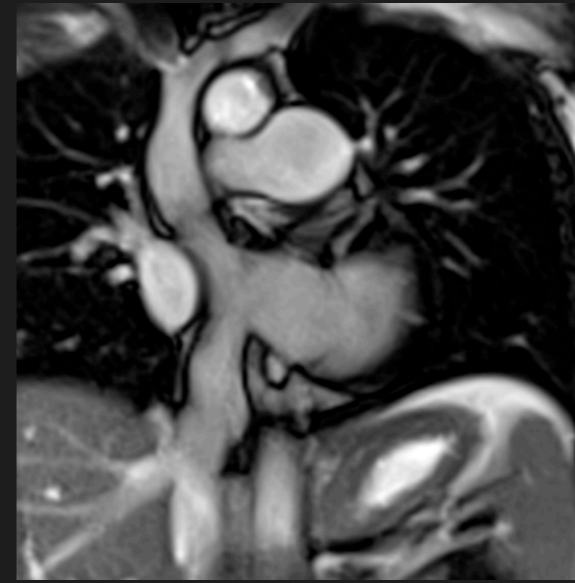
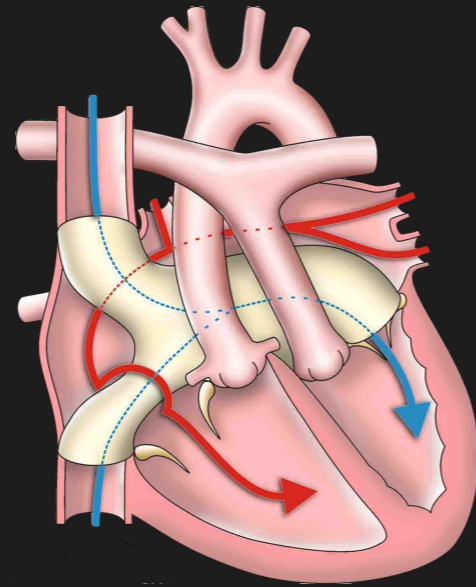
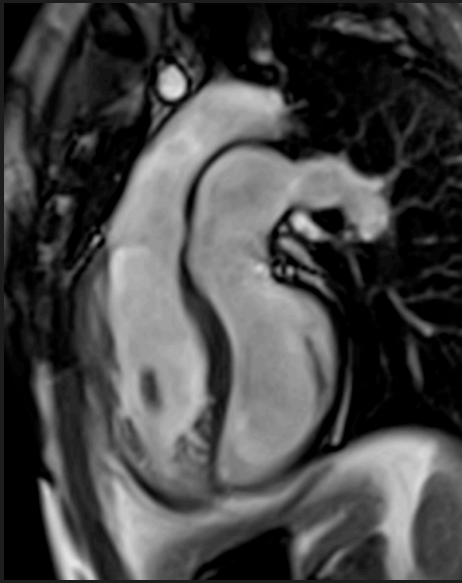


**VA discordance**

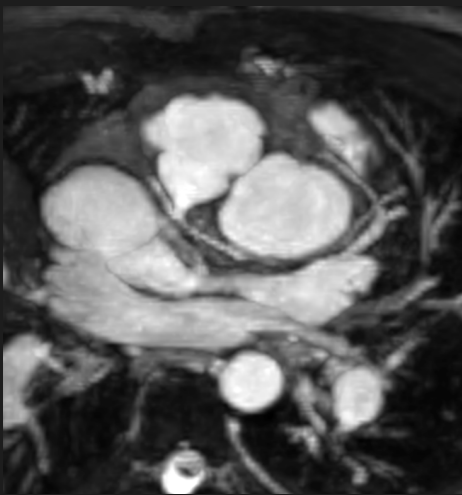


**Cor. off Ao**

# Transposition of the Great Arteries

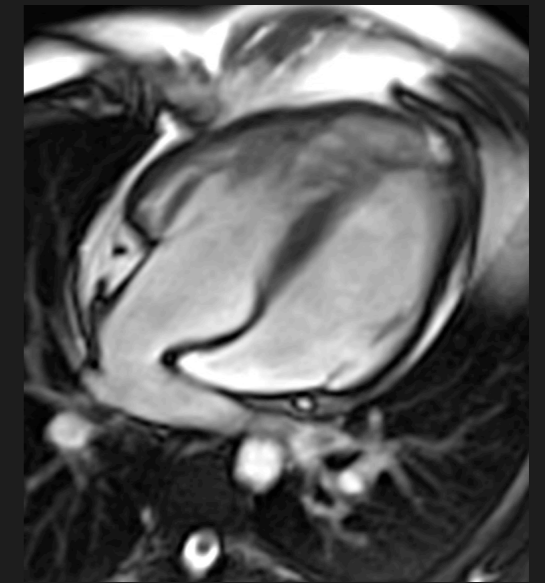
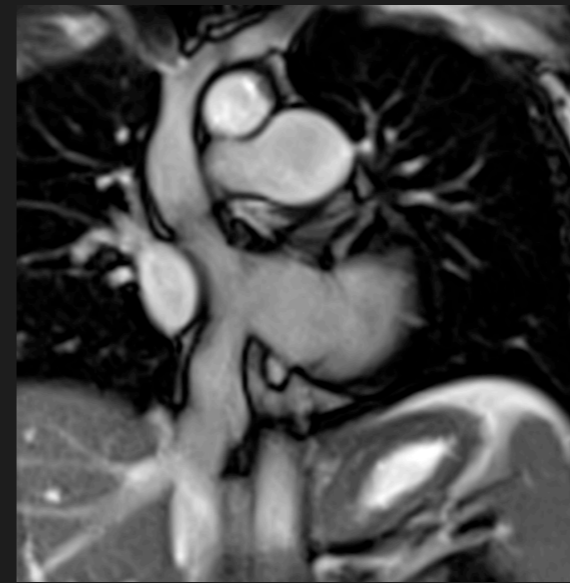
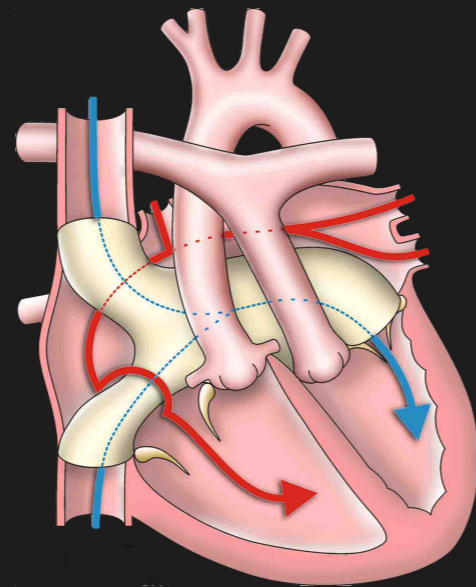
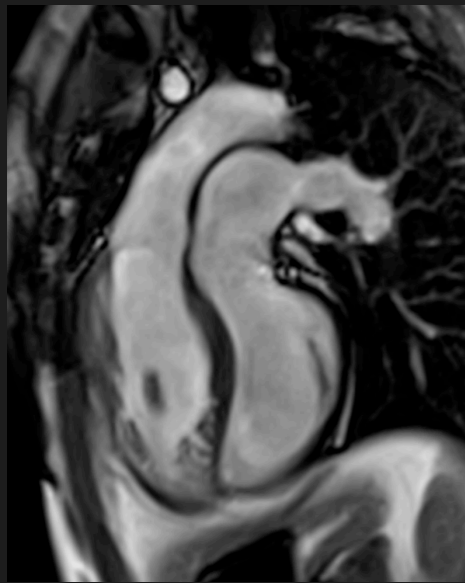


**VA discordance**

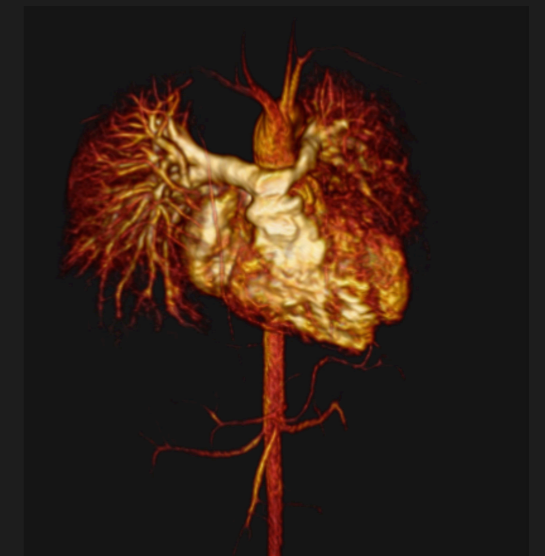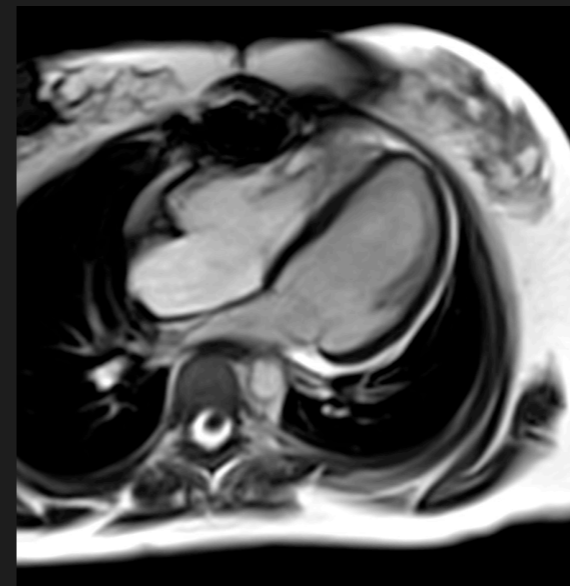
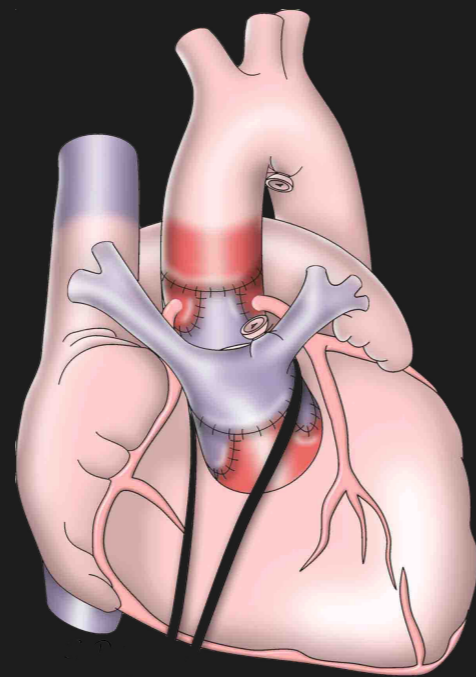
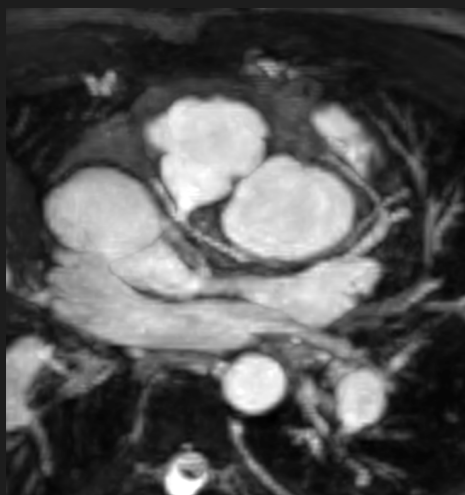


**Cor. off Ao**

# Transposition of the Great Arteries



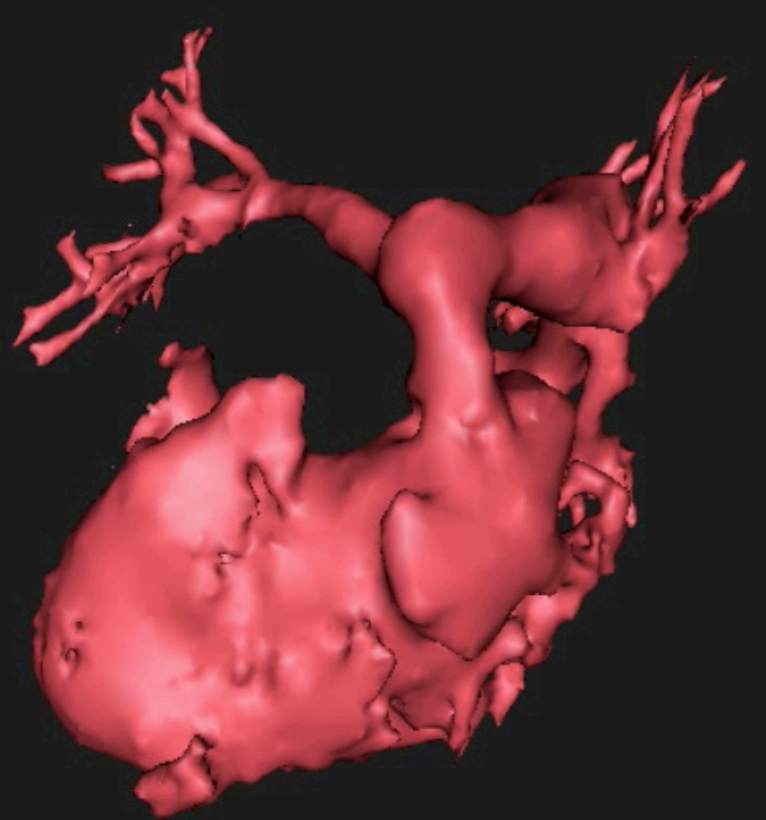
**VA discordance**

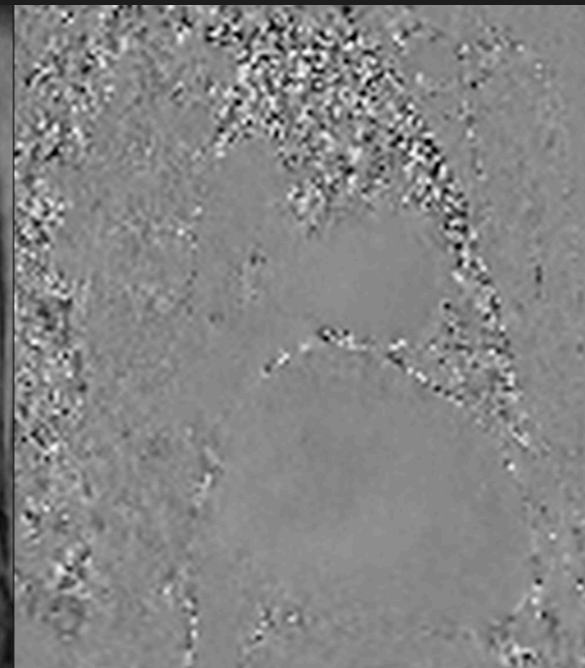
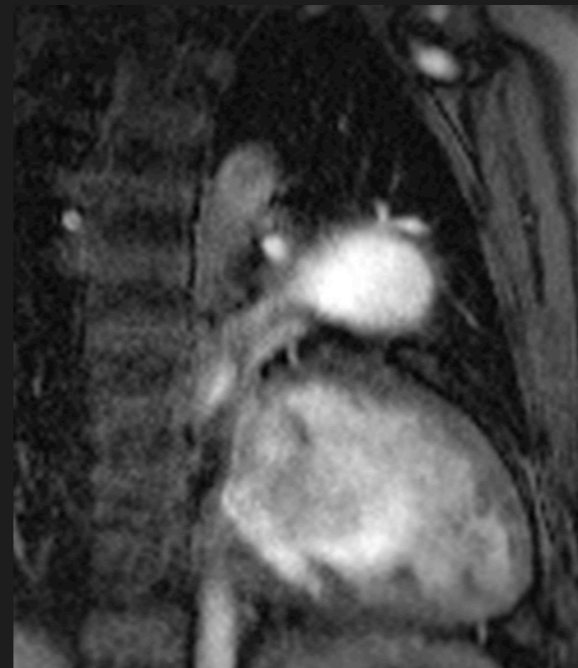
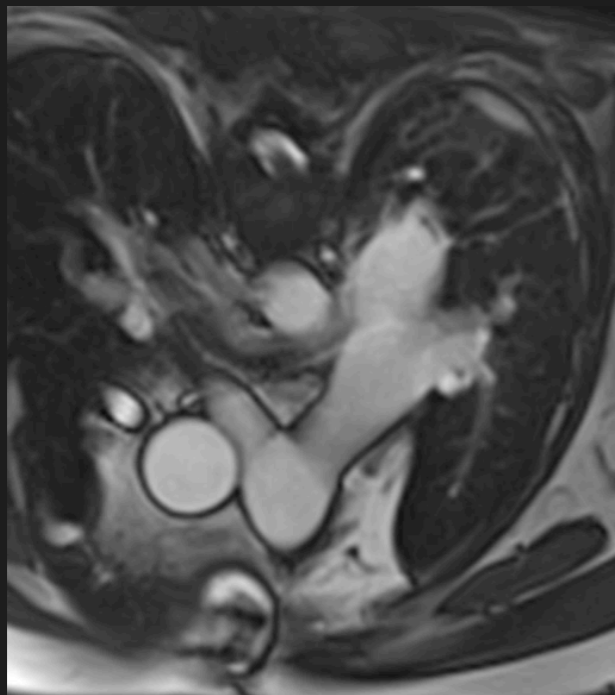
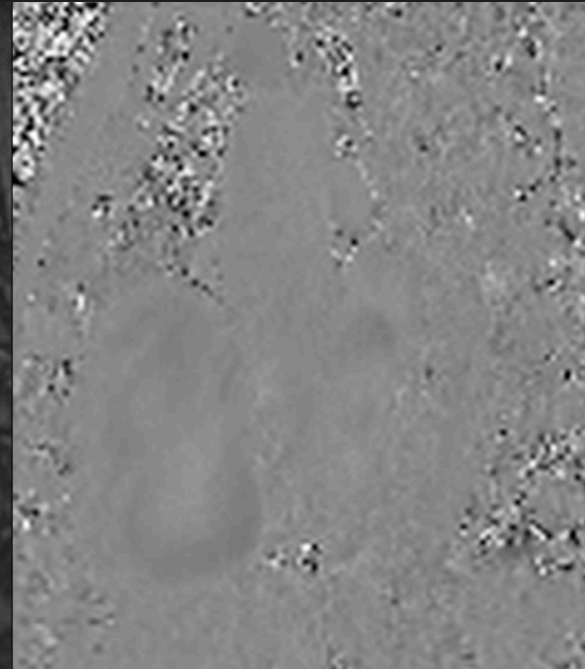
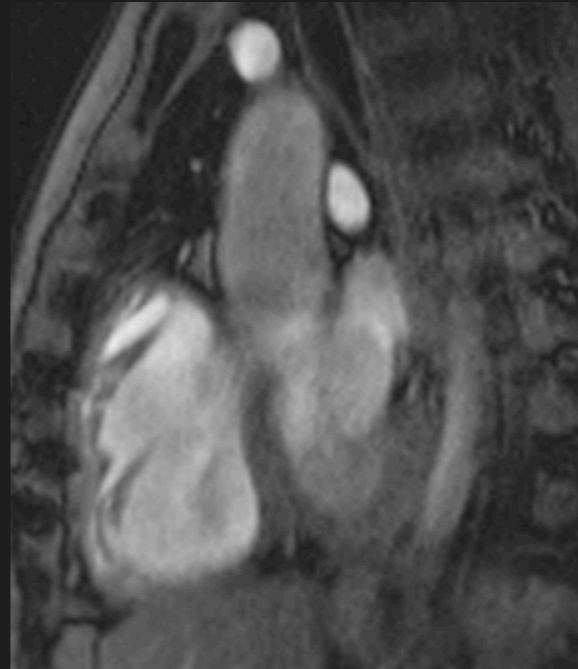
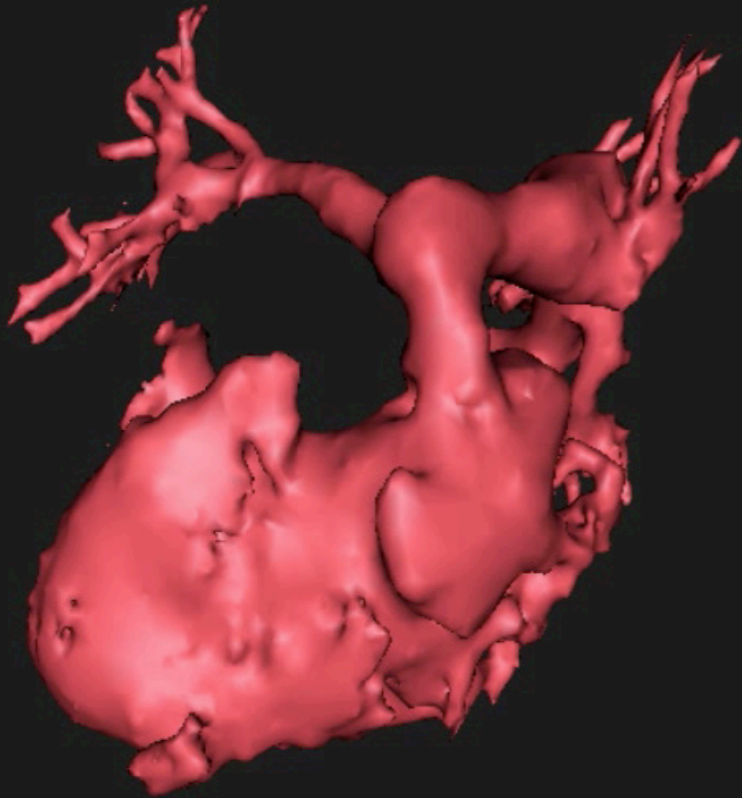


**Cor. off Ao**

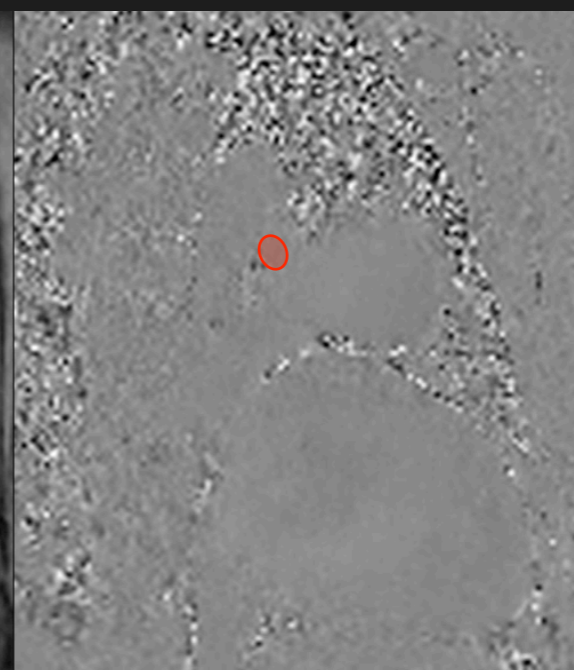
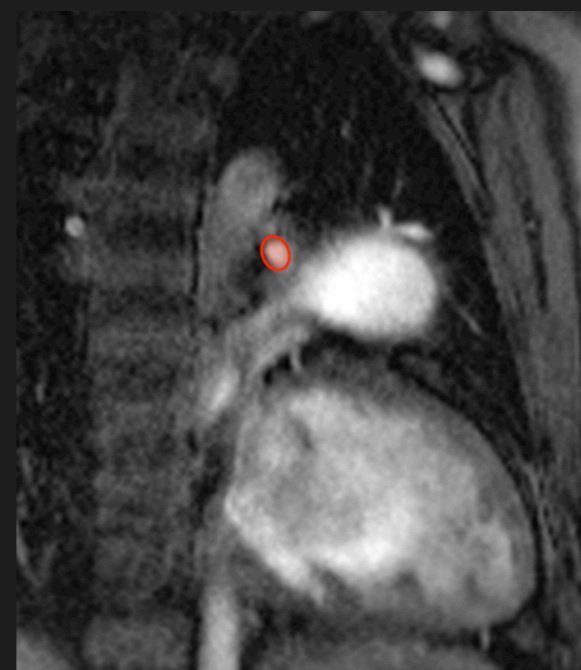
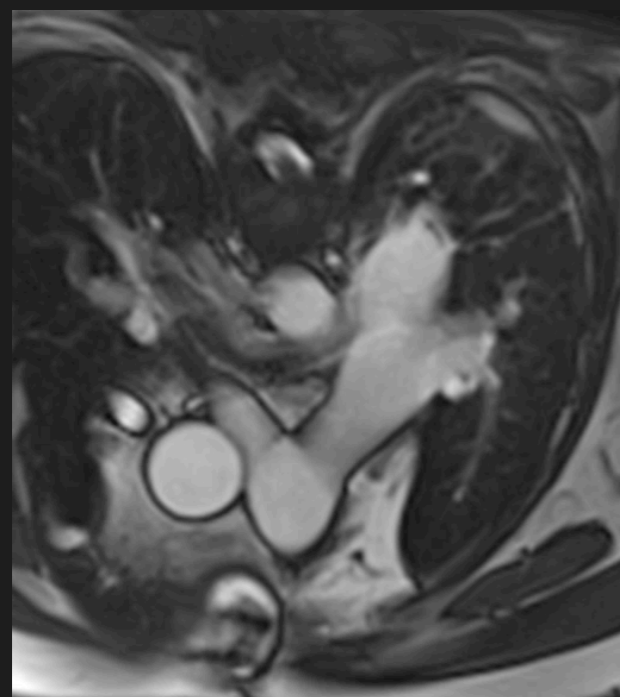
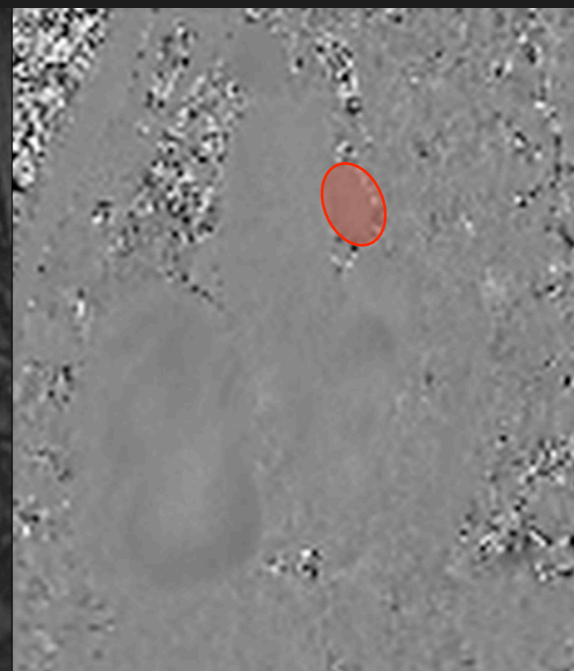
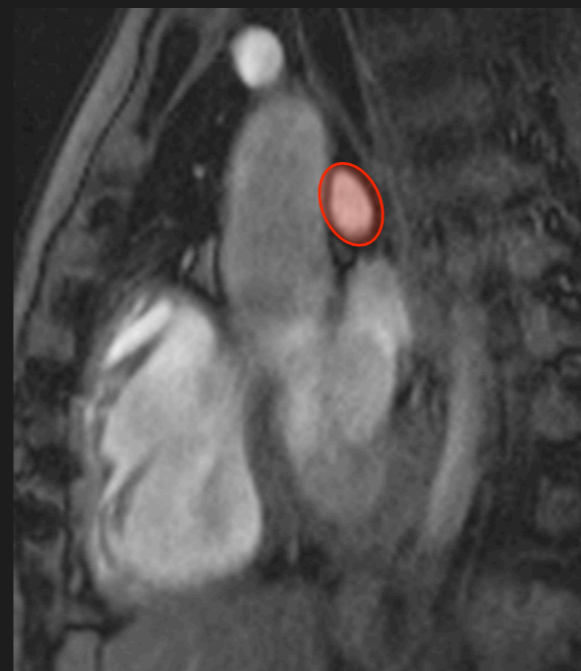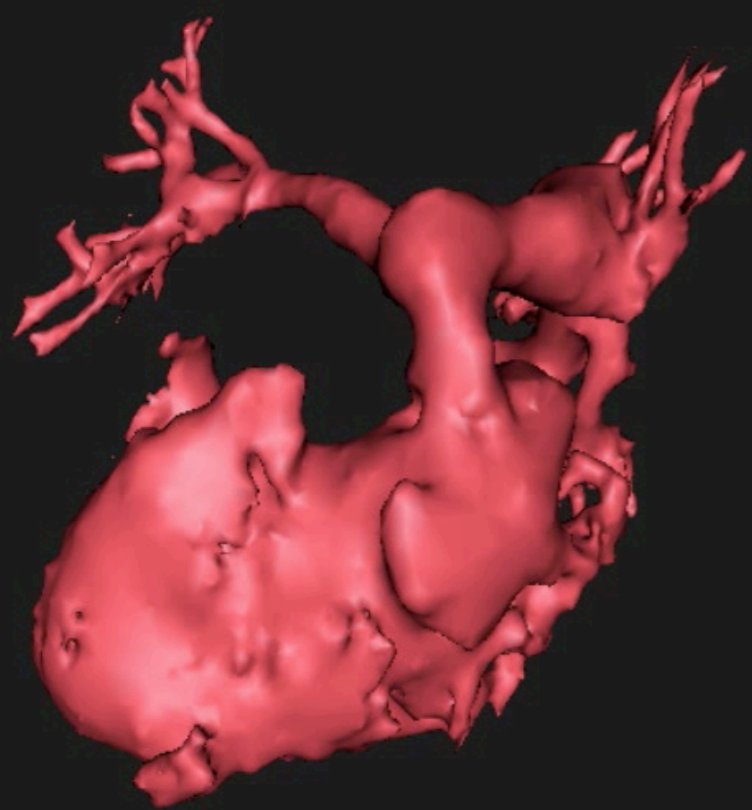


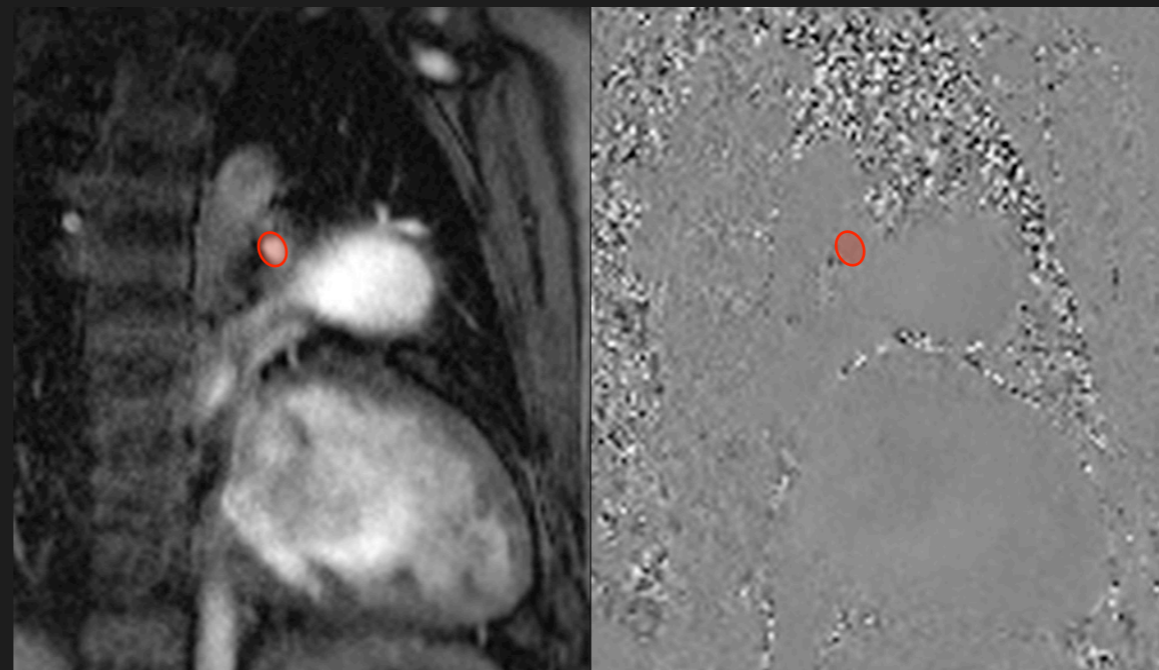
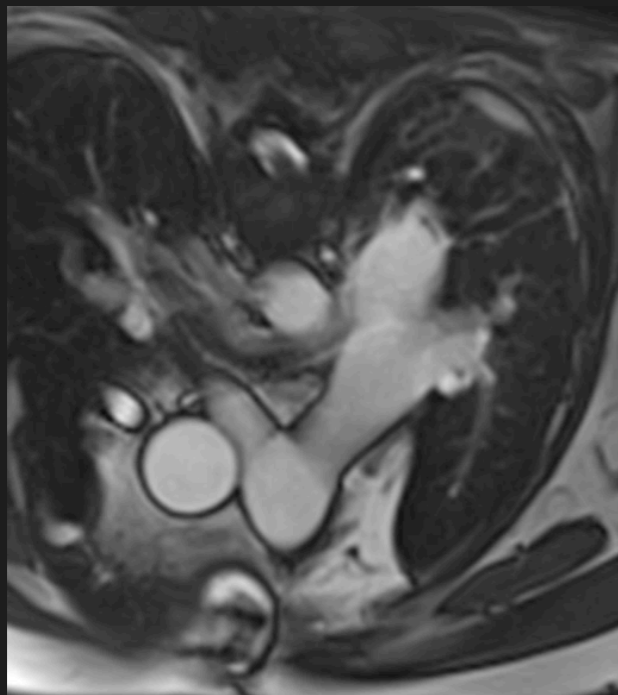
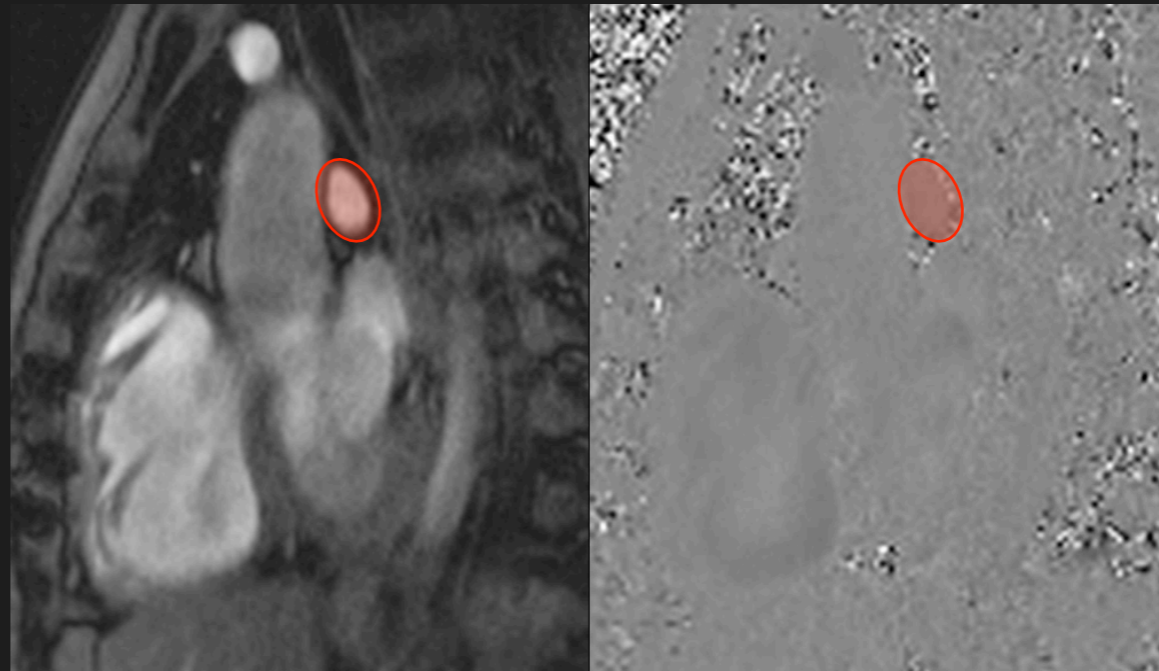
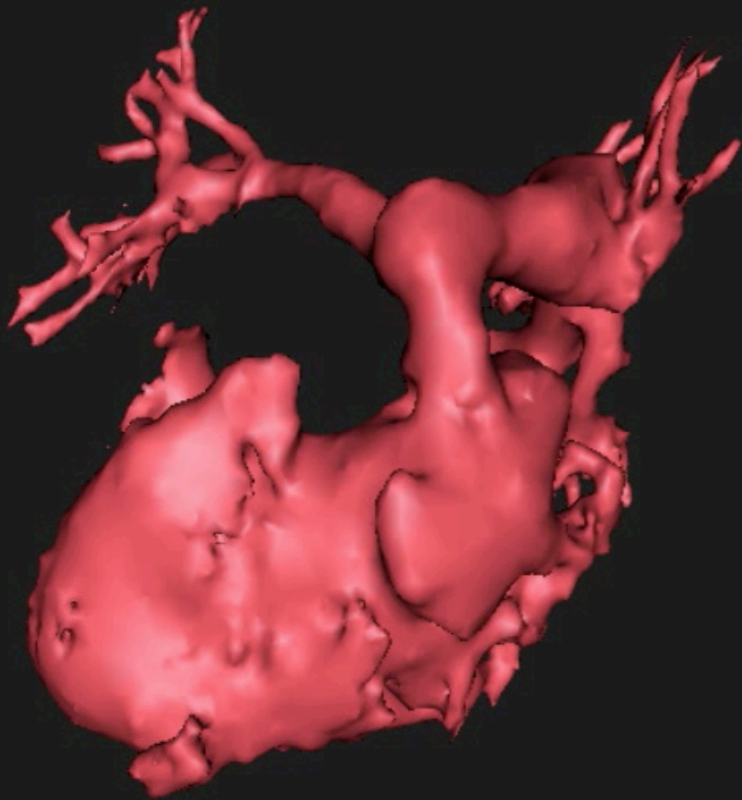
# Branch PA's





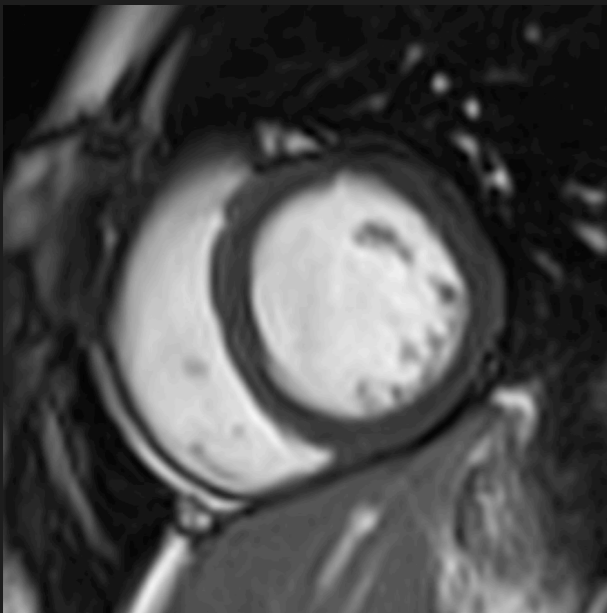
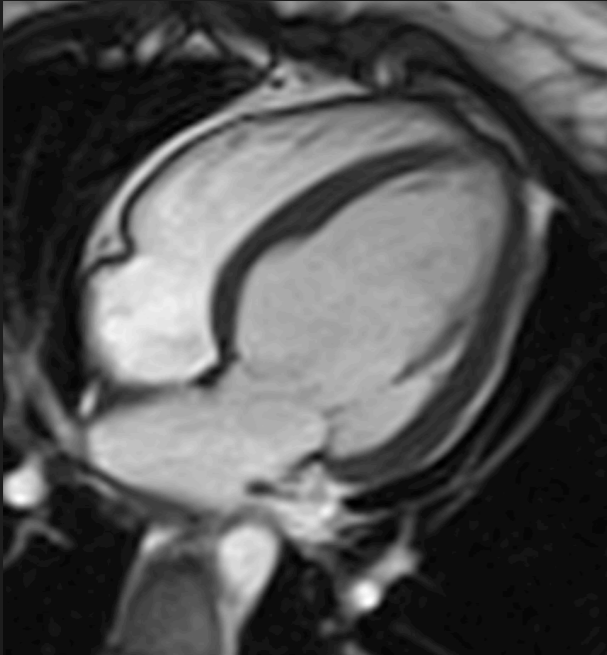
# Branch PA's



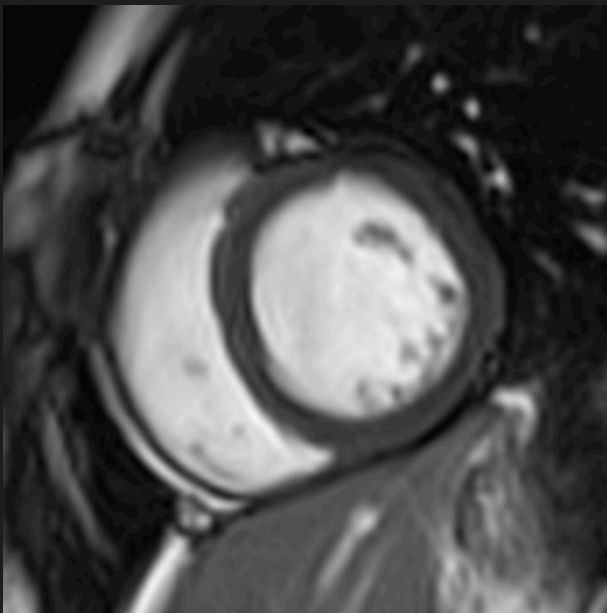
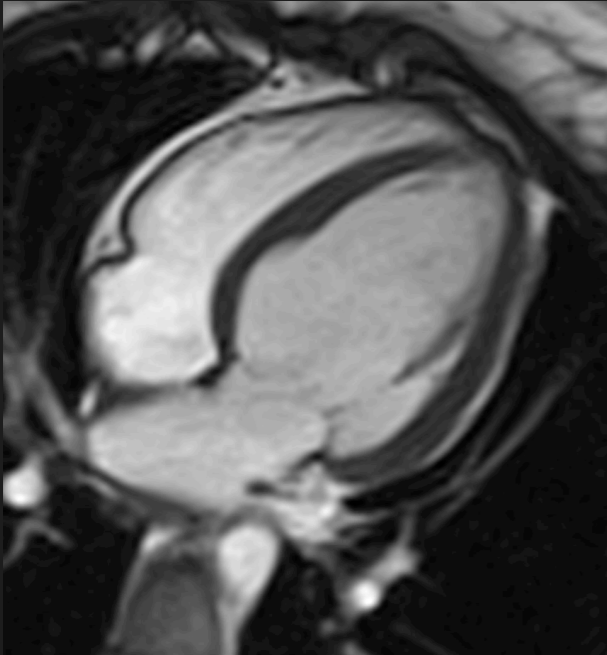


Differential perfusion

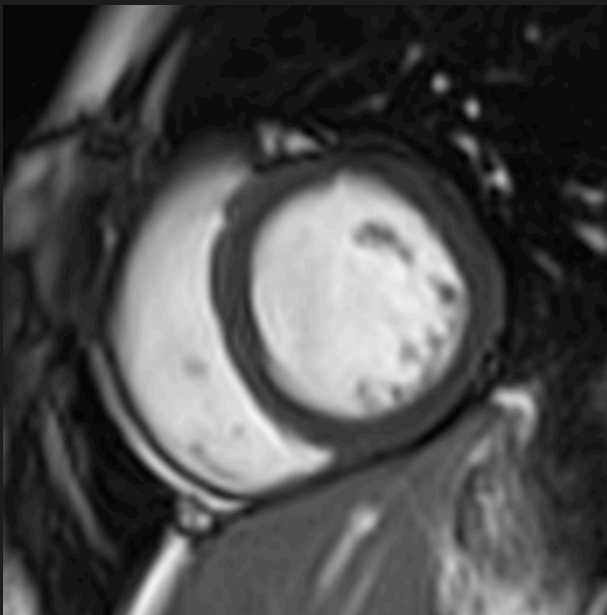
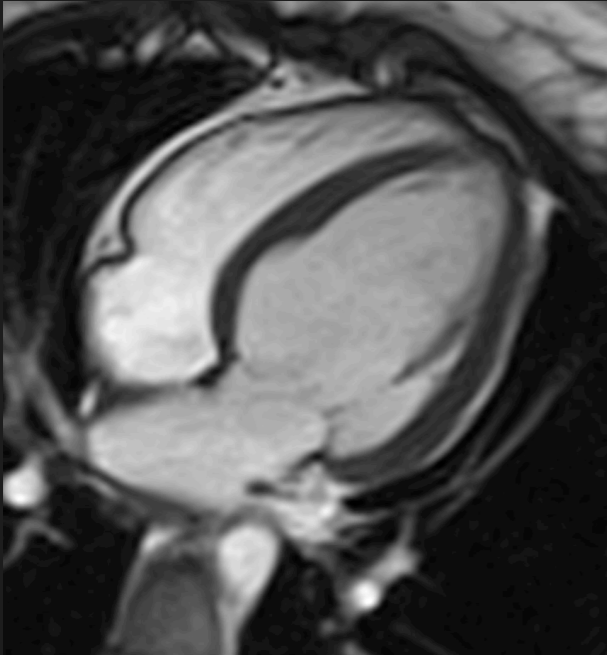
LVH- ?HCM



LVH- ?HCM

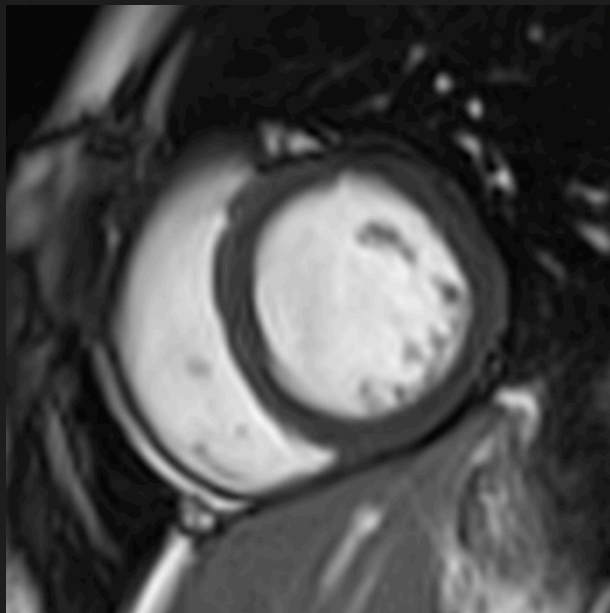
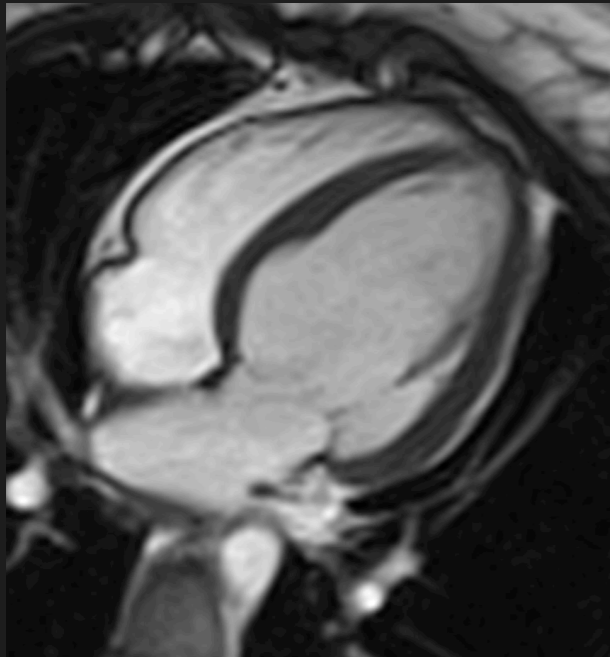


LVH- ?HCM

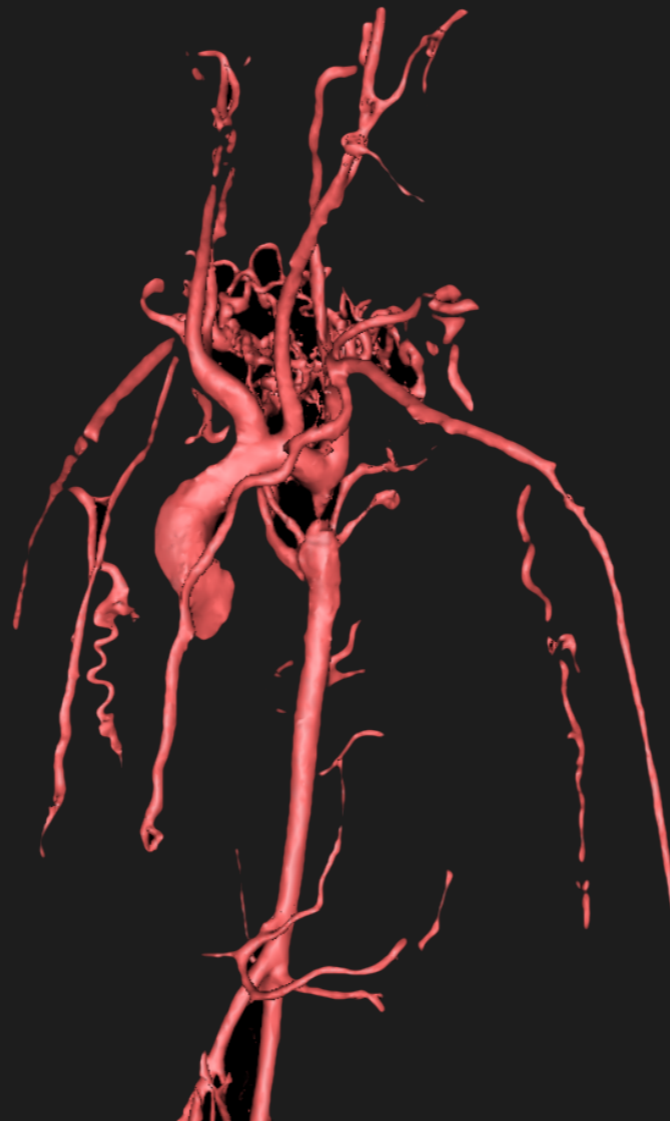


NO aortic stenosis

LVH- ?HCM



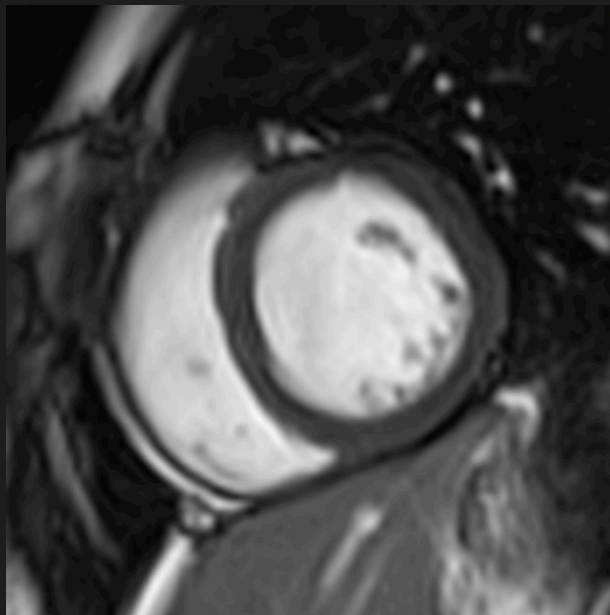
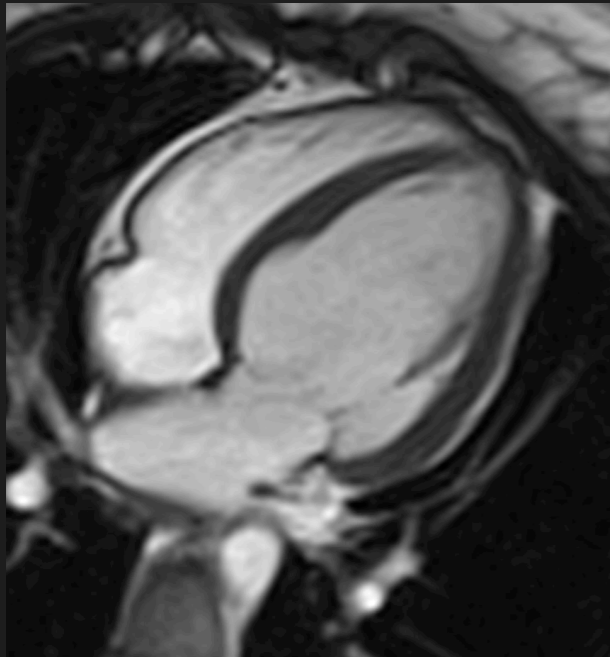
NO aortic stenosis



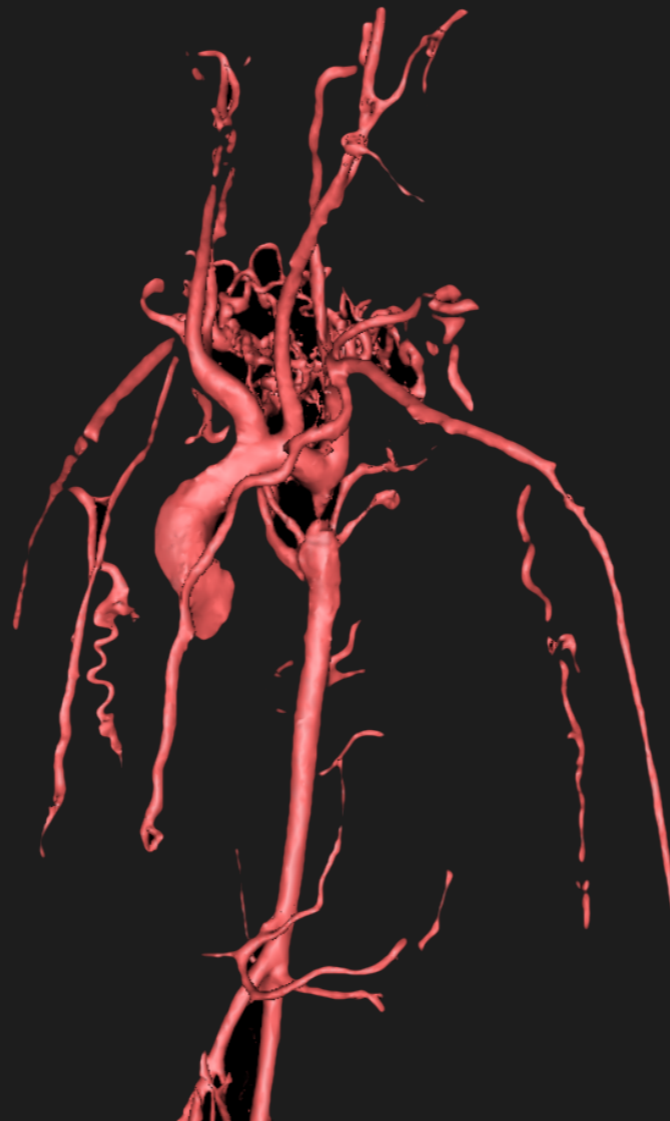
Coarctation



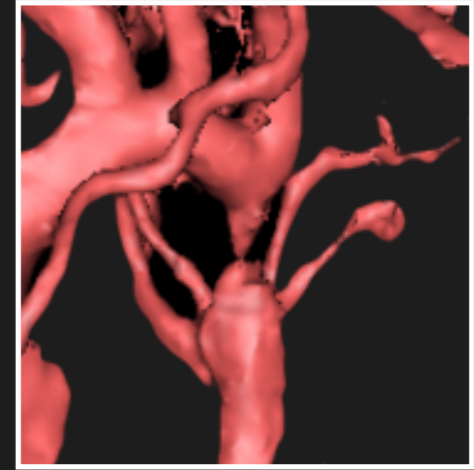
LVH- ?HCM



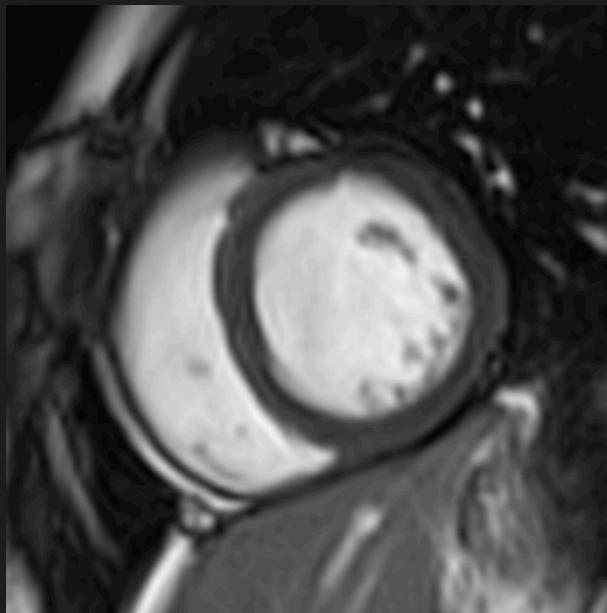
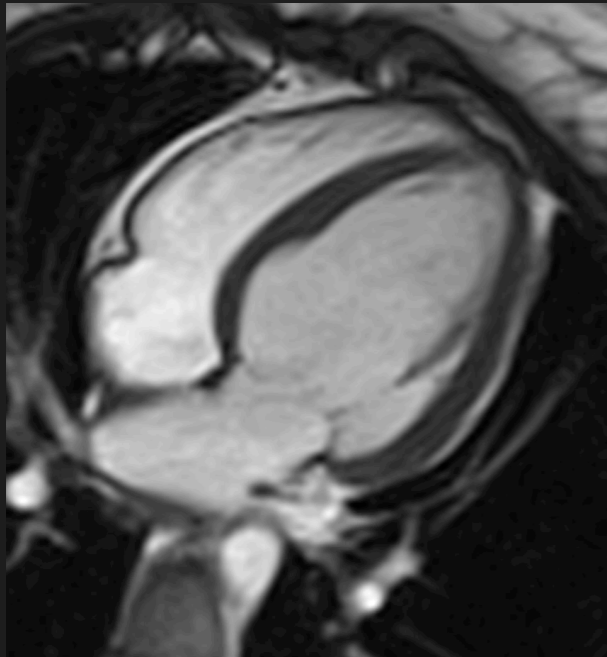
NO aortic stenosis



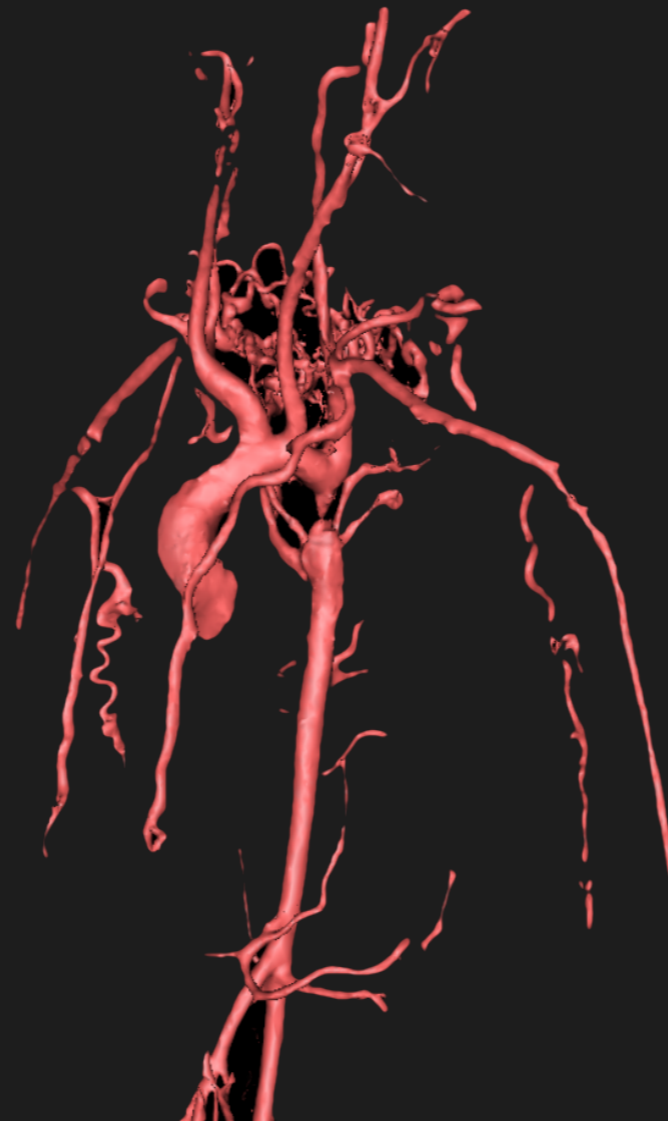
Coarctation



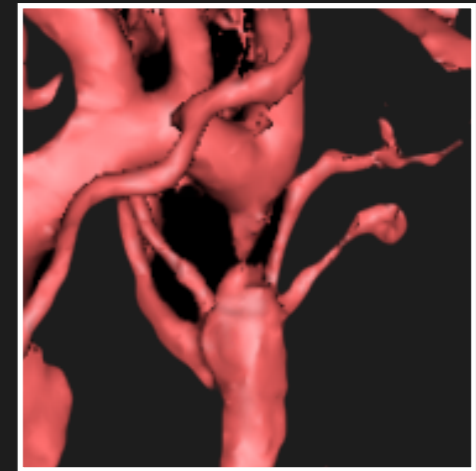
LVH- ?HCM



NO aortic stenosis

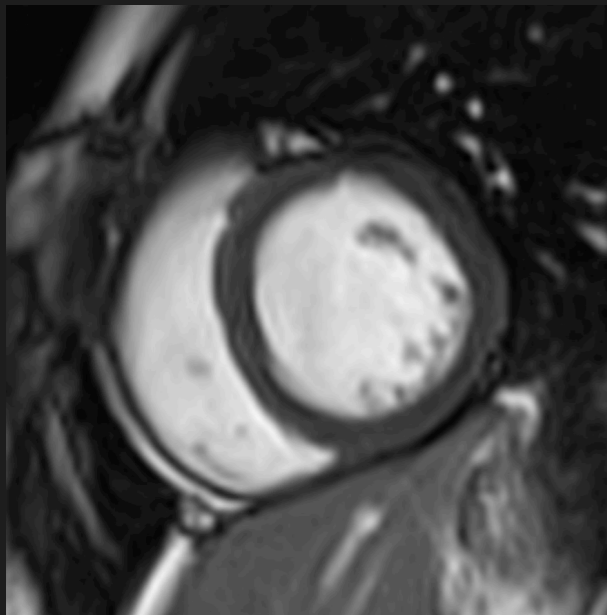
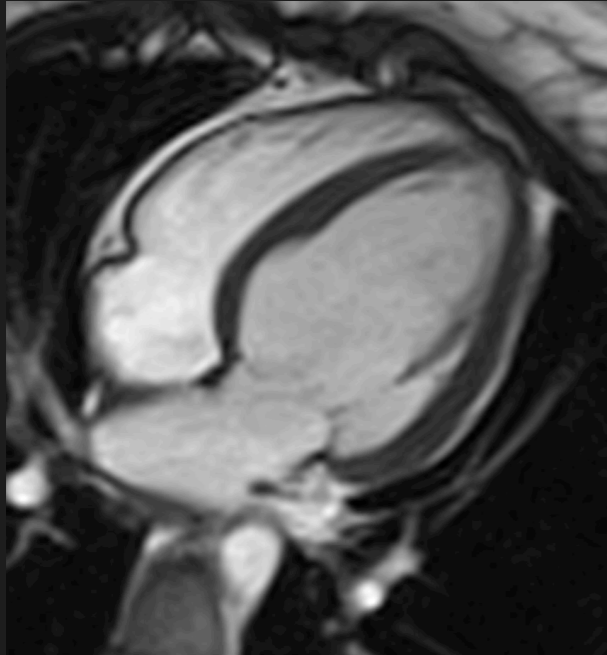


Coarctation

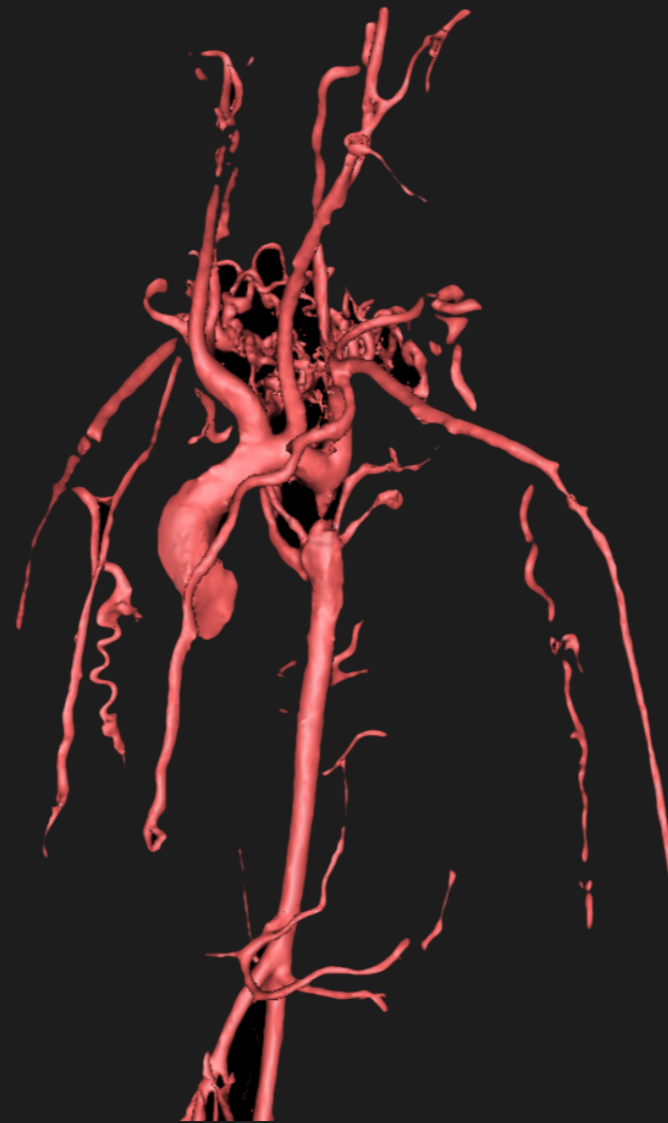


Multiple images

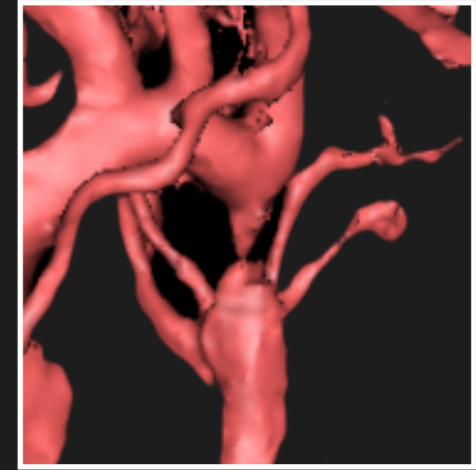
LVH- ?HCM



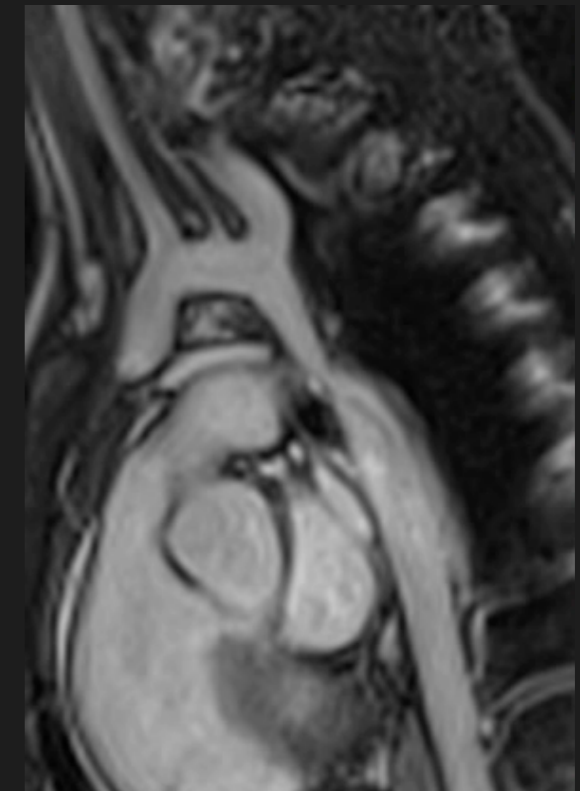
NO aortic stenosis



Coarctation



Multiple images



Ao Stroke Volume	50 mls
PA Stroke Volume	100 mls

$$Q_p:Q_s = 2:1$$

LV Stroke Volume	100 mls
RV Stroke Volume	50 mls

Ao Stroke Volume	50 mls
PA Stroke Volume	100 mls

$$Q_p:Q_s = 2:1$$

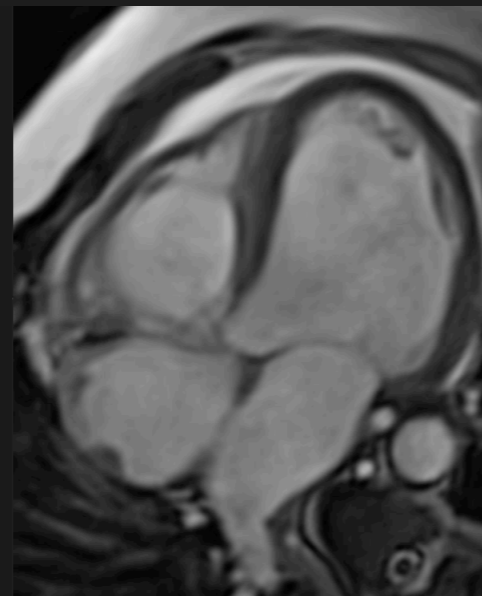
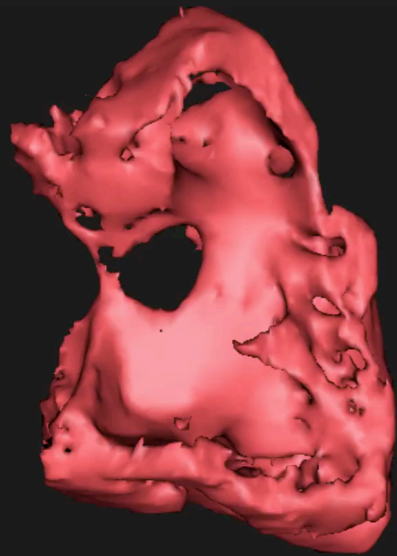
LV Stroke Volume	100 mls
RV Stroke Volume	50 mls

Ao Stroke Volume	50 mls
PA Stroke Volume	100 mls

$$Q_p:Q_s = 2:1$$

LV Stroke Volume	100 mls
RV Stroke Volume	50 mls

## Ventricular septal defect



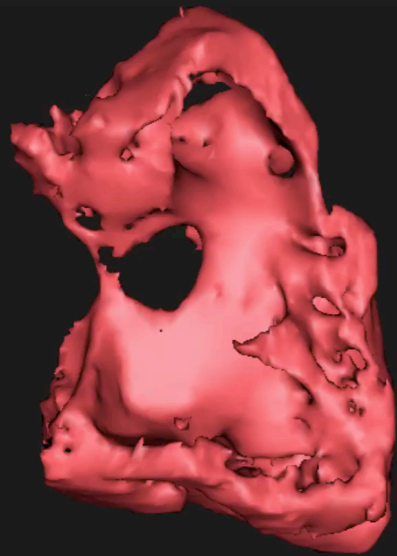
Ao Stroke Volume	50 mls
PA Stroke Volume	100 mls

$$Q_p:Q_s = 2:1$$

LV Stroke Volume	100 mls
RV Stroke Volume	50 mls

Ventricular septal defect

$$LVSV = PASV$$



Ao Stroke Volume	50 mls
PA Stroke Volume	100 mls

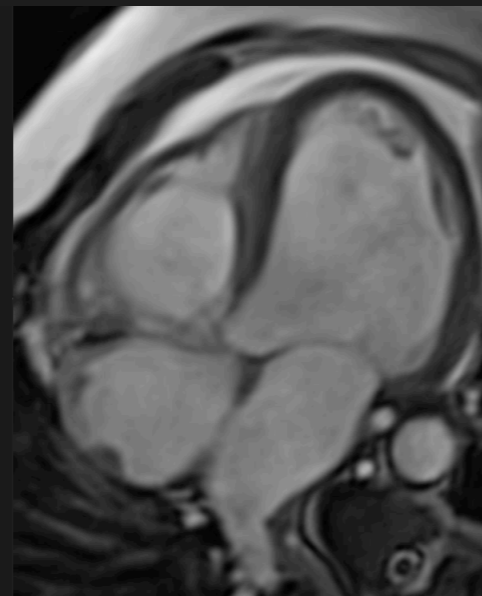
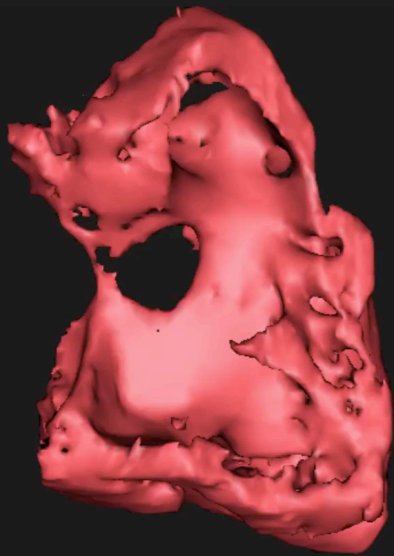
$$Q_p:Q_s = 2:1$$

LV Stroke Volume	100 mls
RV Stroke Volume	50 mls

Ventricular septal defect

$$LVSV = PASV$$

LV volume load - high EDV



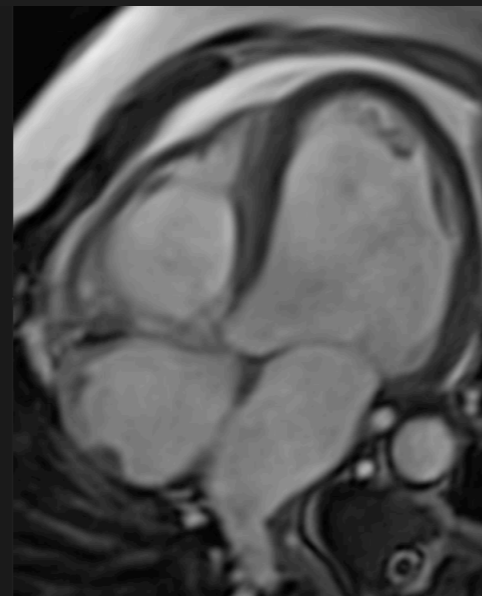
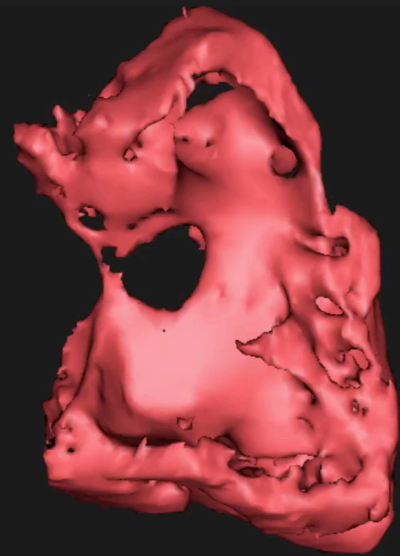


# Dilated Left Heart

Ao Stroke Volume	50 mls
PA Stroke Volume	100 mls

$$Q_p:Q_s = 2:1$$

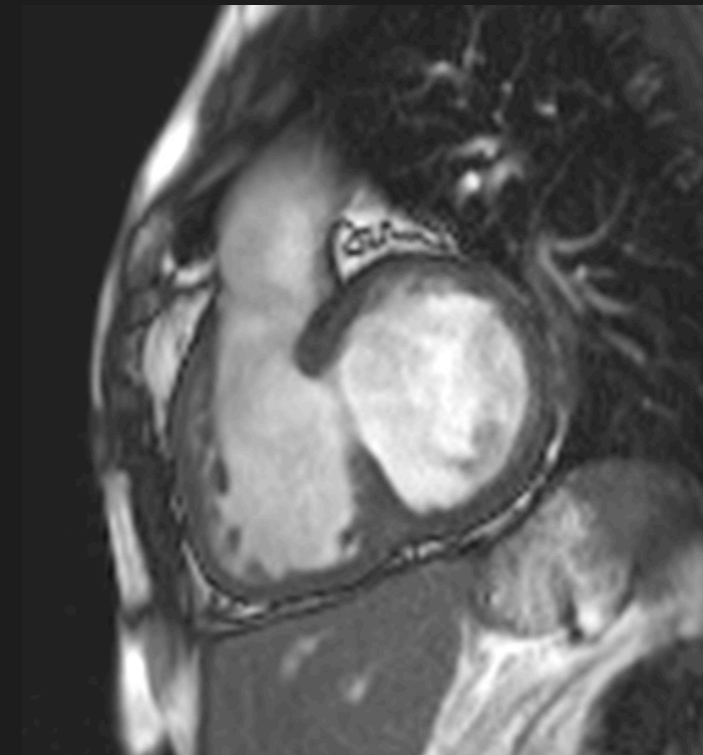
LV Stroke Volume	100 mls
RV Stroke Volume	50 mls



Ventricular septal defect

$$LVSV = PASV$$

LV volume load - high EDV

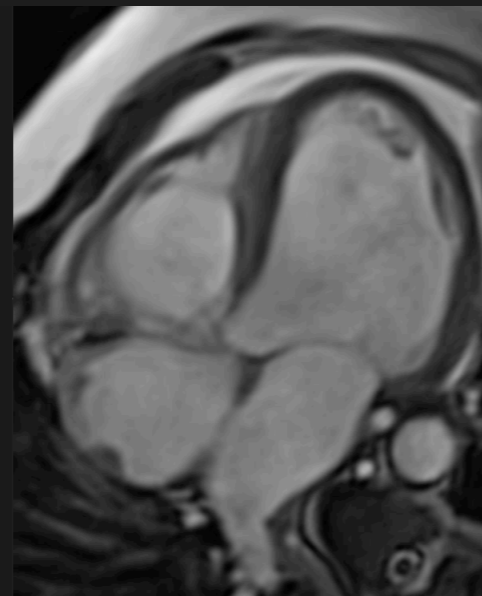
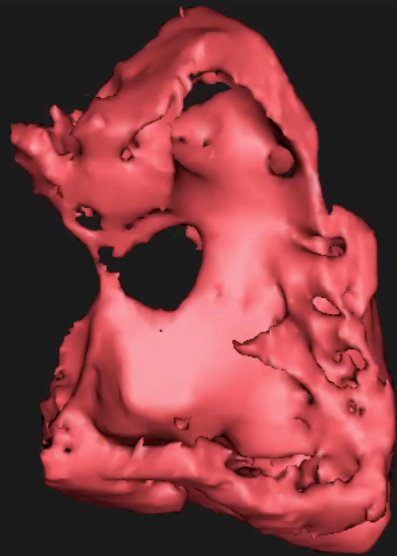


Reversal if RV pressure high

Ao Stroke Volume	50 mls
PA Stroke Volume	100 mls

$$Q_p:Q_s = 2:1$$

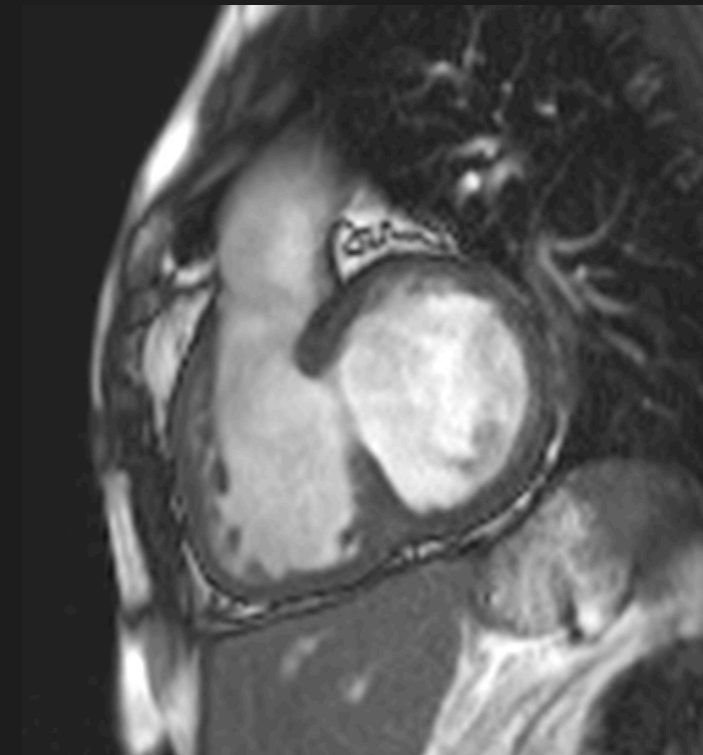
LV Stroke Volume	100 mls
RV Stroke Volume	50 mls



Ventricular septal defect

$$LVSV = PASV$$

LV volume load - high EDV



Reversal if RV pressure high

$$RVSV = AoSV$$



**Measure Ao & PA flow**

Measure Ao & PA flow

$Q_p:Q_s < 1$

**Measure Ao & PA flow**

**$Q_p:Q_s < 1$**

**Suggest R>L shunt**

Measure Ao & PA flow

$Q_p:Q_s < 1$

Suggest R>L shunt

Ao Stroke Volume	100 mls
PA Stroke Volume	50 mls

LV Stroke Volume	100 mls
RV Stroke Volume	50 mls

**R>L ASD**

**Measure Ao & PA flow**

**$Q_p:Q_s < 1$**

**Suggest R>L shunt**

**Child acyanotic**

Ao Stroke Volume	100 mls
PA Stroke Volume	50 mls

LV Stroke Volume	100 mls
RV Stroke Volume	50 mls

**R>L ASD**



**Measure Ao & PA flow**

**$Q_p:Q_s < 1$**

**Suggest R>L shunt**

**Child acyanotic**

Ao Stroke Volume	100 mls
PA Stroke Volume	50 mls
PV Stroke Volume	100 mls
LV Stroke Volume	100 mls
RV Stroke Volume	50 mls

**R>L ASD**

**Measure Ao & PA flow**

**$Q_p:Q_s < 1$**

**Suggest R>L shunt**

**Child acyanotic**

Ao Stroke Volume	100 mls
PA Stroke Volume	50 mls
PV Stroke Volume	100 mls
LV Stroke Volume	100 mls
RV Stroke Volume	50 mls

**R>L ASD**

Measure Ao & PA flow

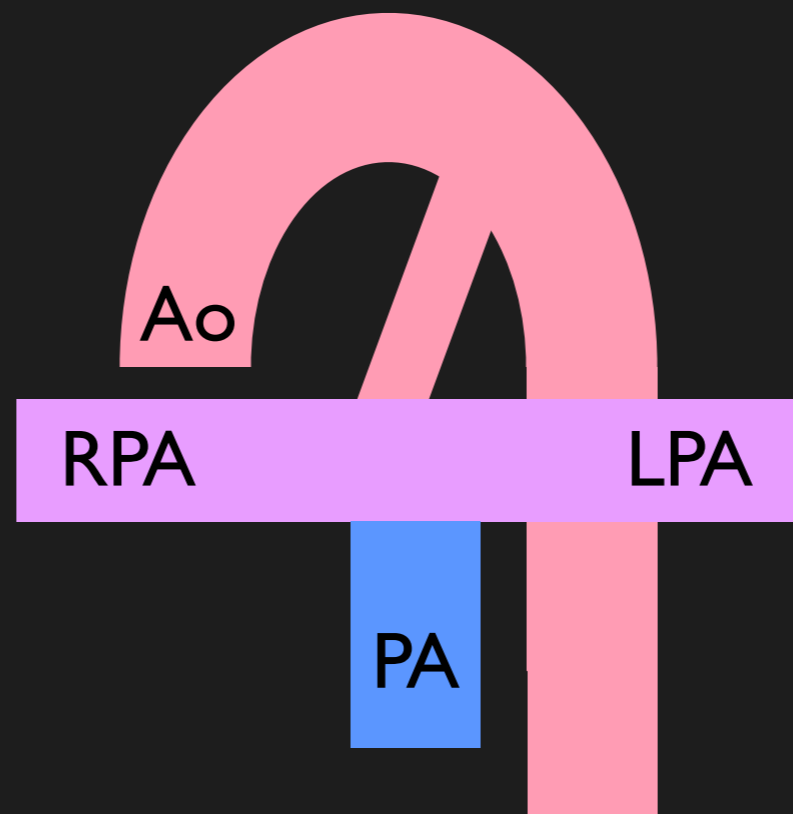
$Q_p:Q_s < 1$

Suggest R>L shunt

Child acyanotic

Ao Stroke Volume	100 mls
PA Stroke Volume	50 mls
PV Stroke Volume	100 mls
LV Stroke Volume	100 mls
RV Stroke Volume	50 mls

**R>L ASD**



Measure Ao & PA flow

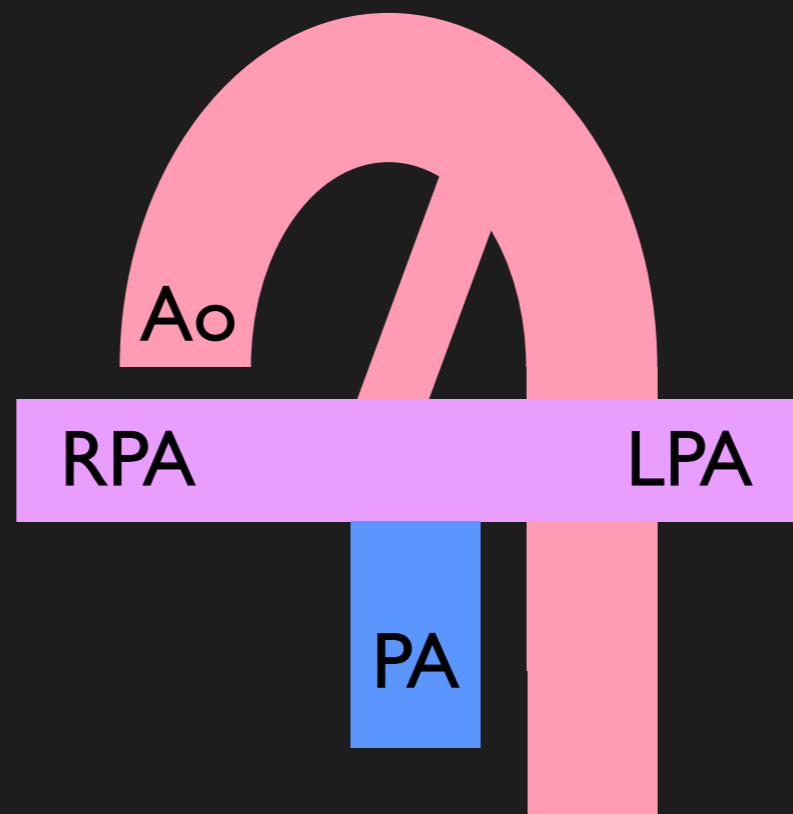
$Q_p:Q_s < 1$

Suggest R>L shunt

Child acyanotic

Ao Stroke Volume	100 mls
PA Stroke Volume	50 mls
PV Stroke Volume	100 mls
LV Stroke Volume	100 mls
RV Stroke Volume	50 mls

**R>L ASD**



Ao = 100 mls

Measure Ao & PA flow

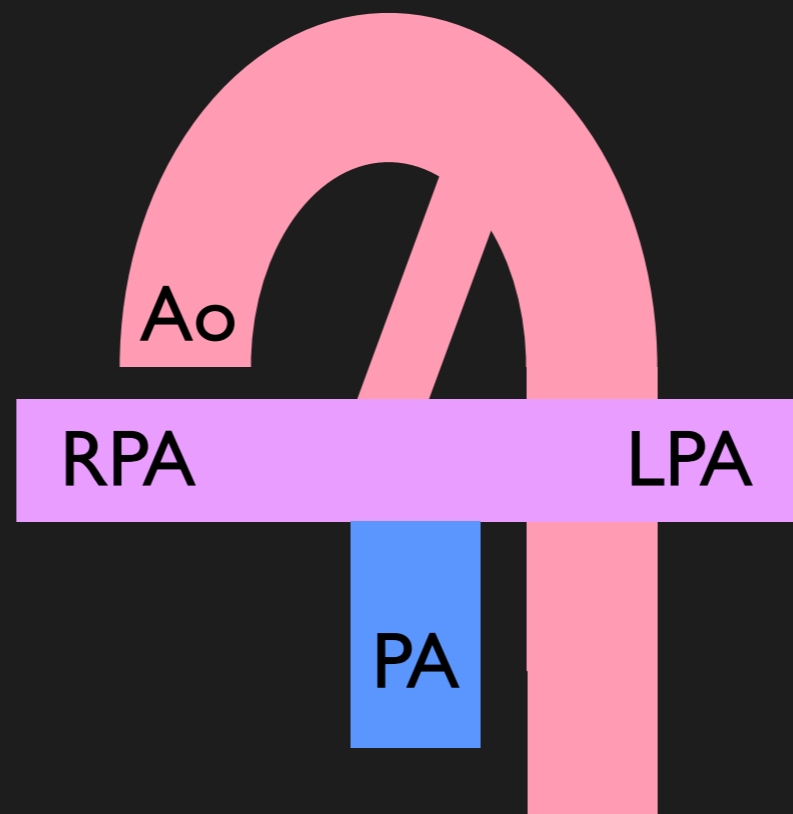
$Q_p:Q_s < 1$

Suggest R>L shunt

Child acyanotic

Ao Stroke Volume	100 mls
PA Stroke Volume	50 mls
PV Stroke Volume	100 mls
LV Stroke Volume	100 mls
RV Stroke Volume	50 mls

**R>L ASD**



Ao = 100 mls

PA = 50 mls

Measure Ao & PA flow

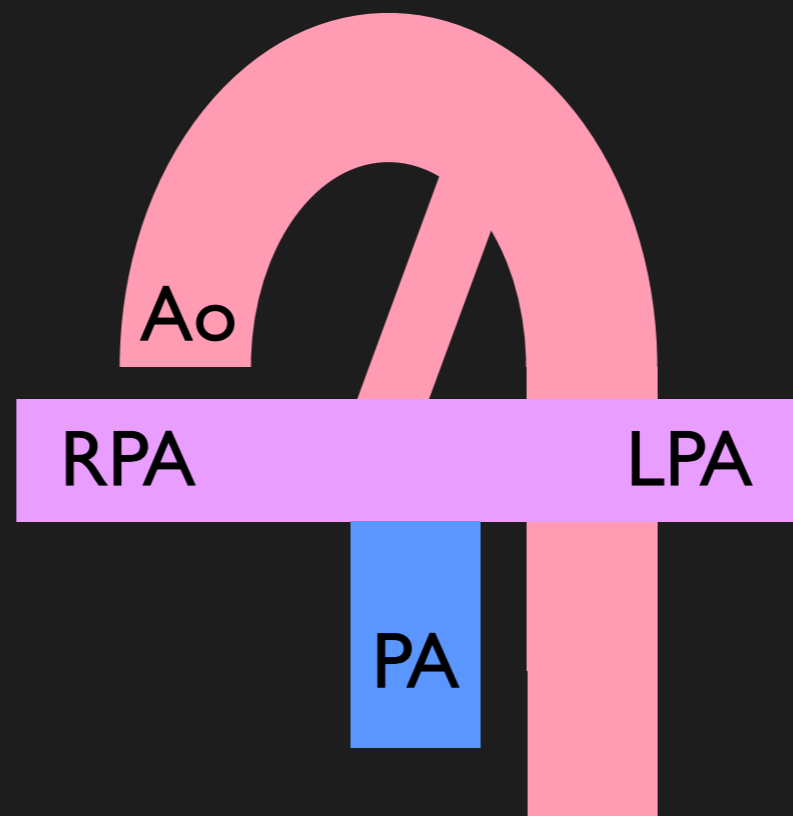
$Q_p:Q_s < 1$

Suggest R>L shunt

Child acyanotic

Ao Stroke Volume	100 mls
PA Stroke Volume	50 mls
PV Stroke Volume	100 mls
LV Stroke Volume	100 mls
RV Stroke Volume	50 mls

**R>L ASD**



Ao = 100 mls

PA = 50 mls

PDA = 50 mls

Measure Ao & PA flow

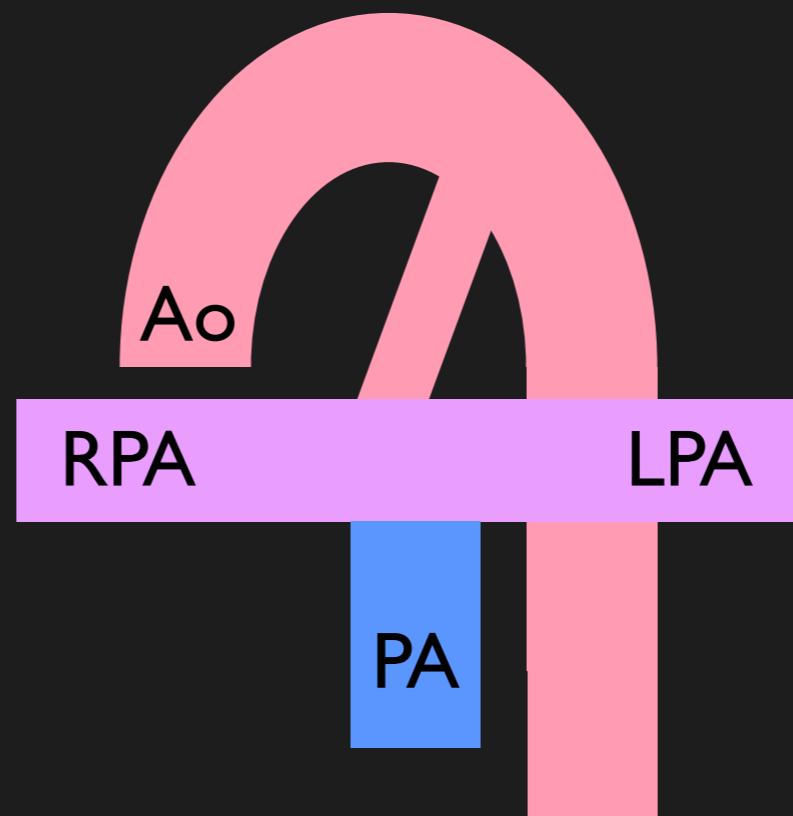
$Q_p:Q_s < 1$

Suggest R>L shunt

Child acyanotic

Ao Stroke Volume	100 mls
PA Stroke Volume	50 mls
PV Stroke Volume	100 mls
LV Stroke Volume	100 mls
RV Stroke Volume	50 mls

**R>L ASD**

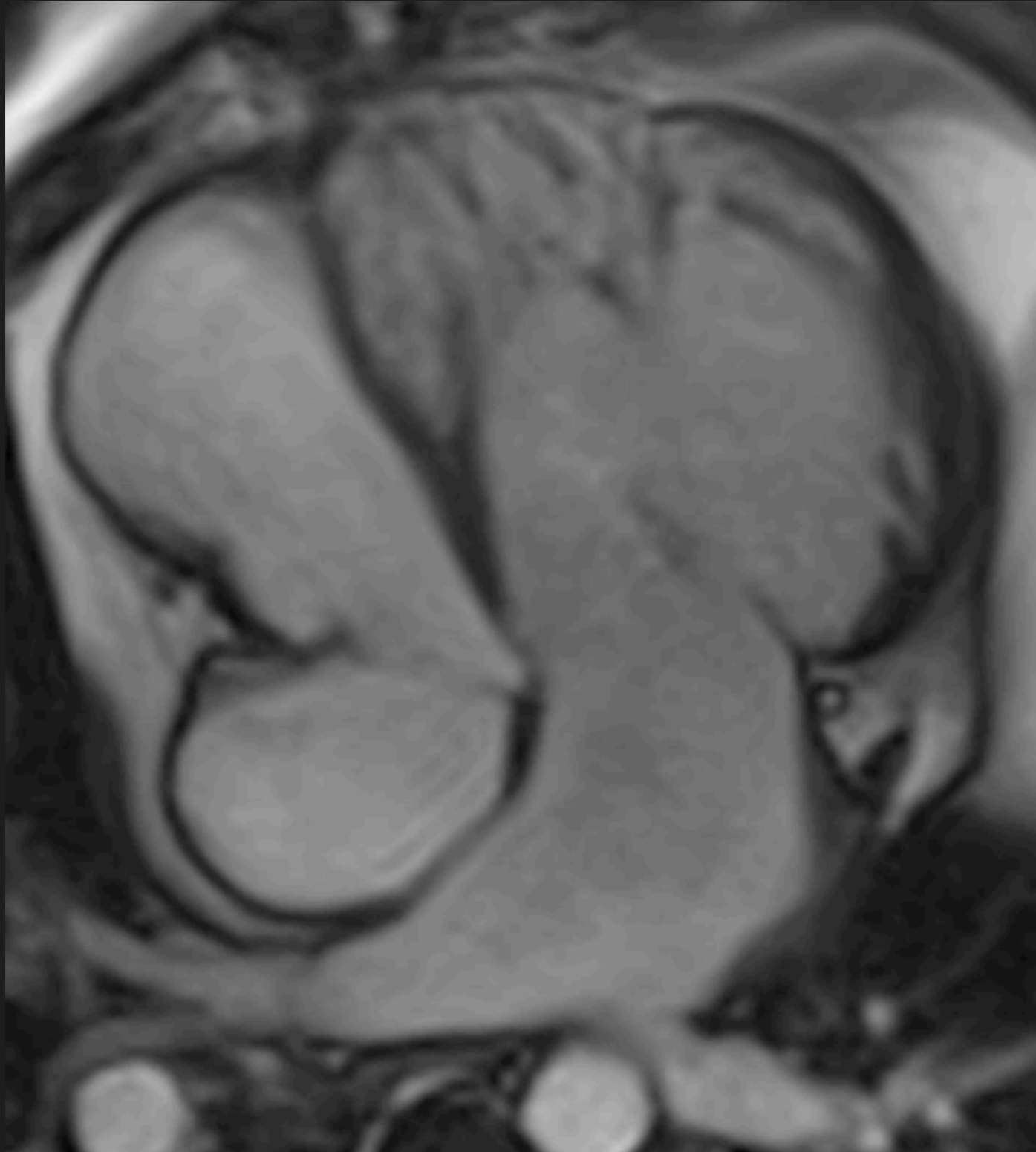


Ao = 100 mls

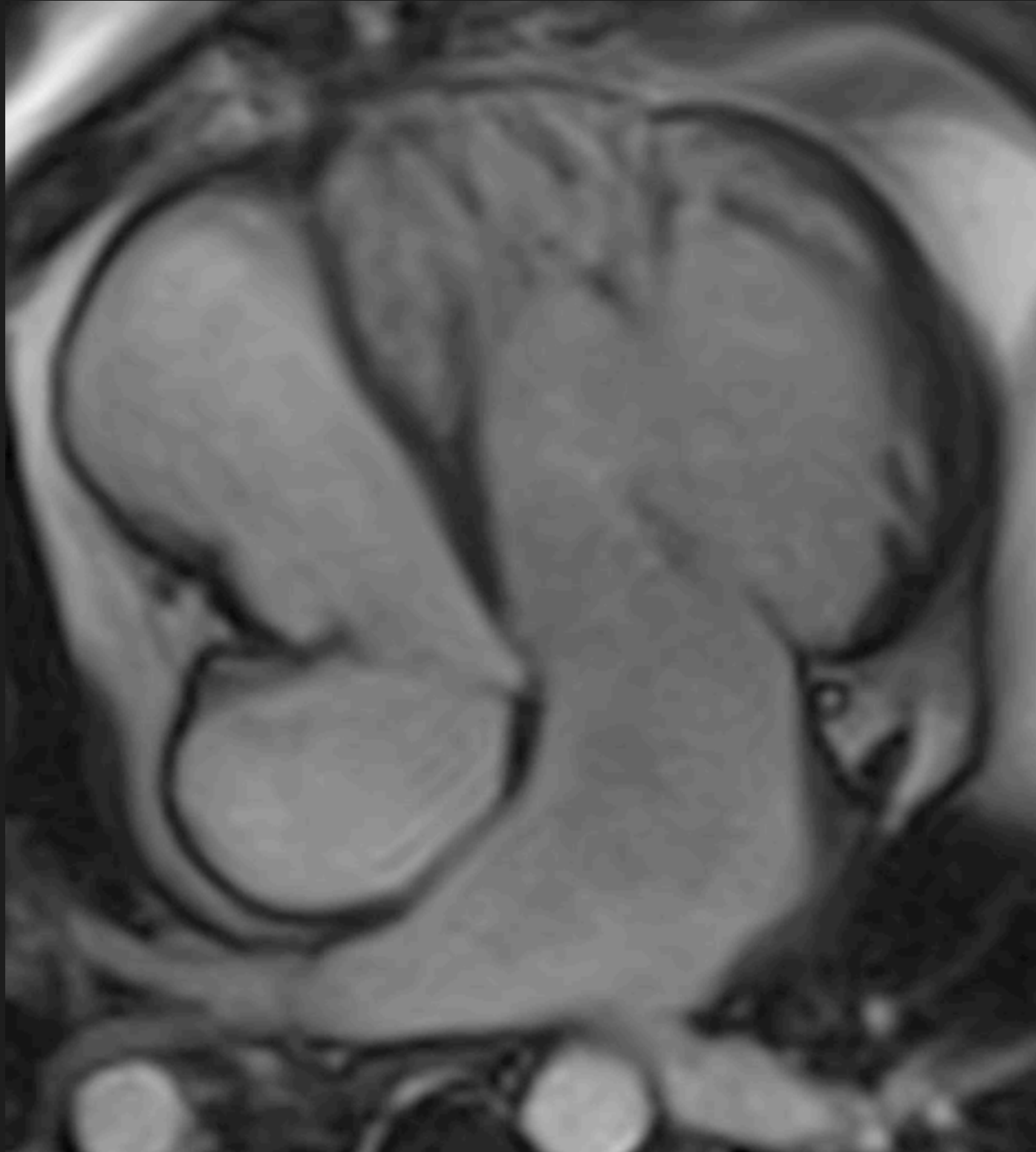
PA = 50 mls

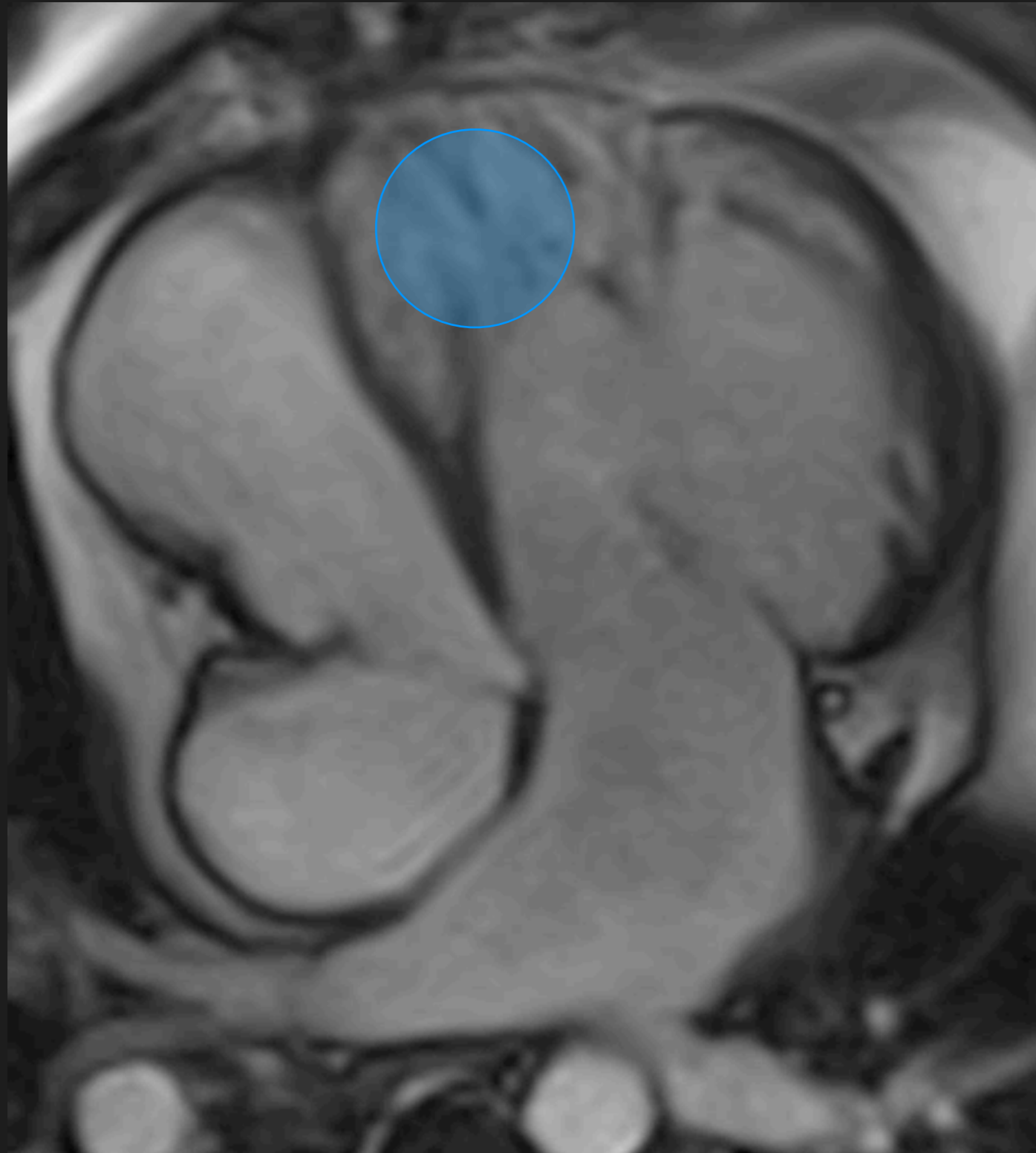
PDA = 50 mls

BPA = 100 mls





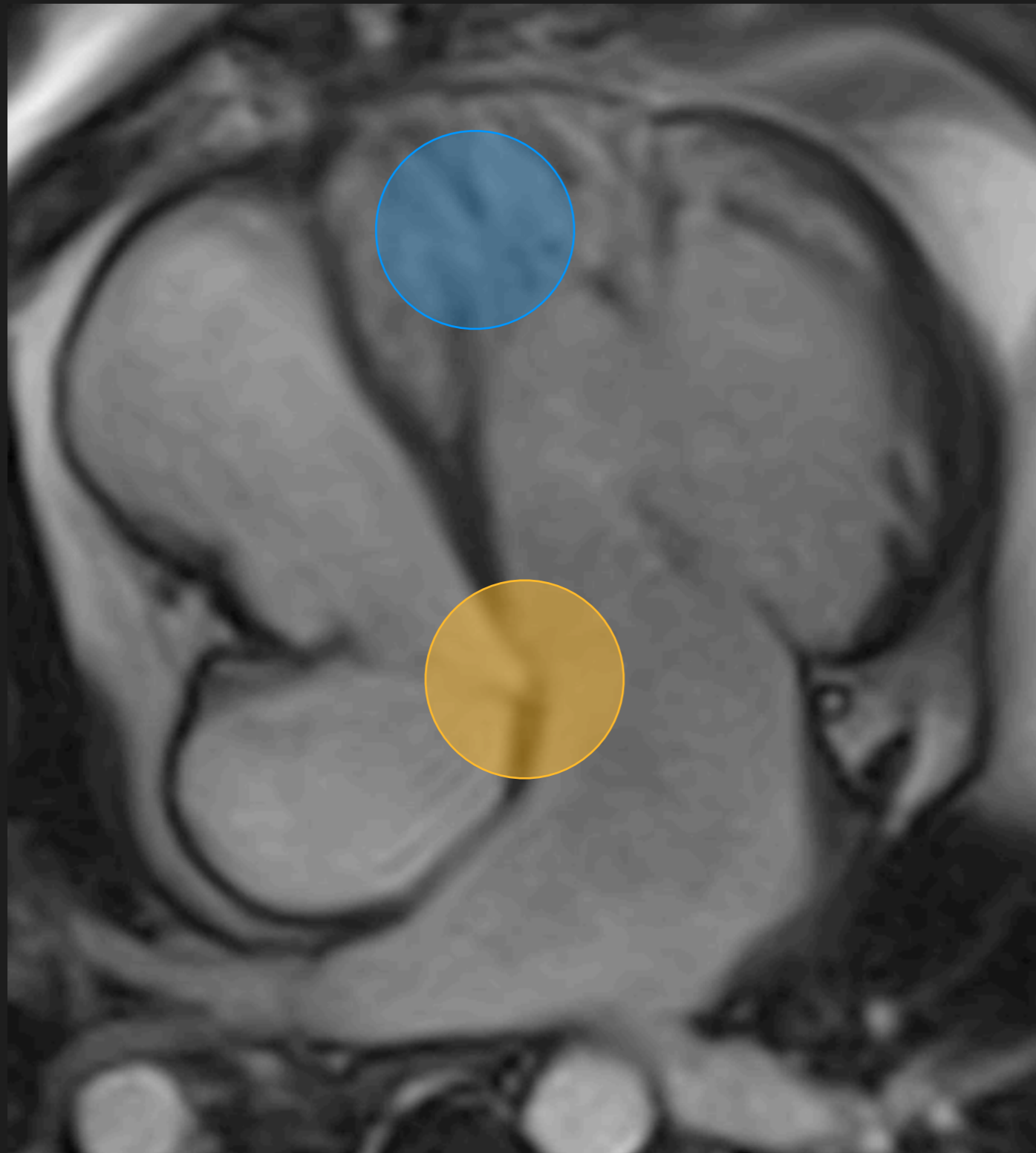




## Ventricular architecture

Irregular trabeculations

Moderator band



## Ventricular architecture

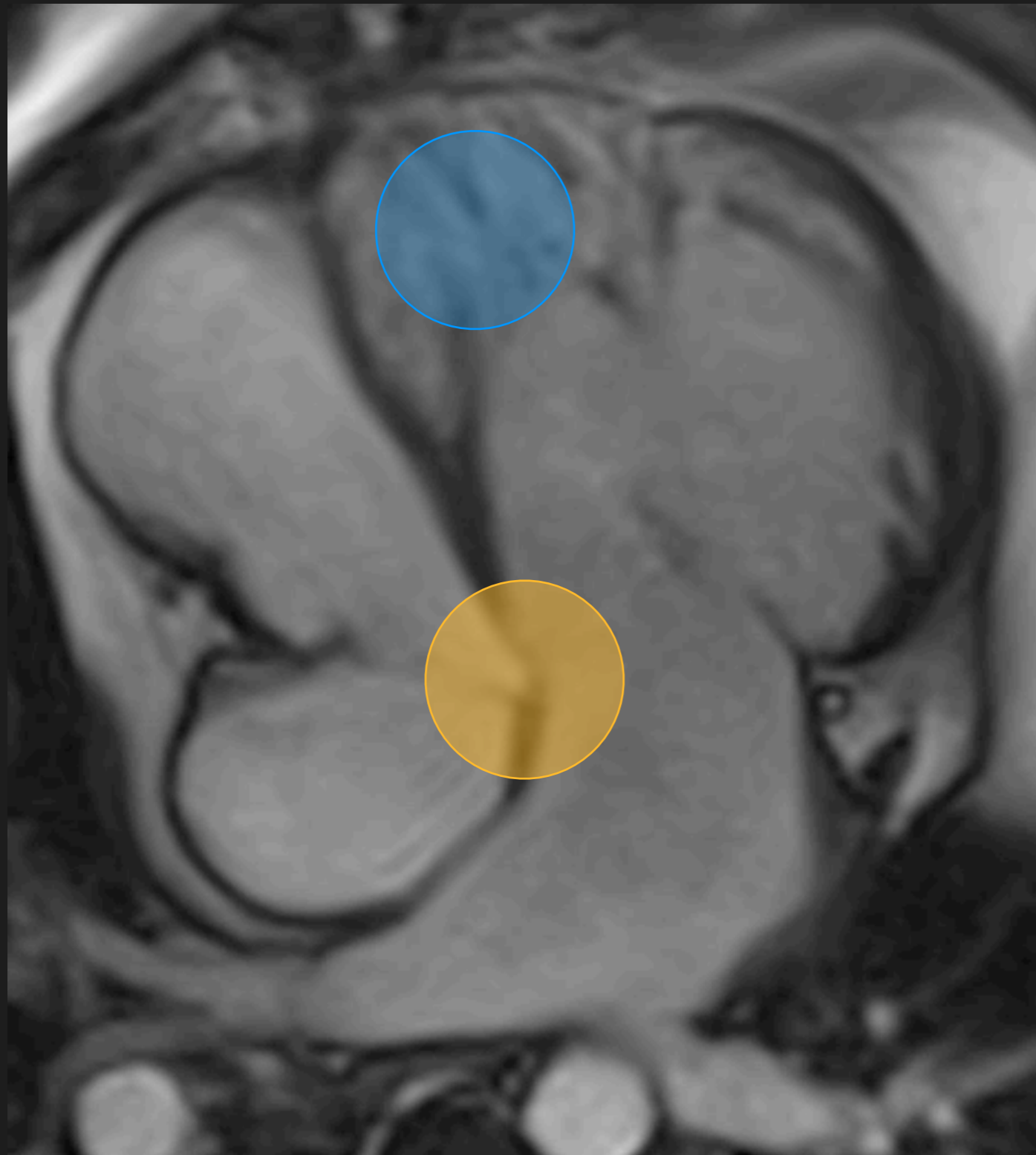
Irregular trabeculations

Moderator band

## Tricuspid Valve

Apical off-setting of RAVV

Tri-leaflet valve



## Ventricular architecture

Irregular trabeculations

Moderator band

## Tricuspid Valve

Apical off-setting of RAVV

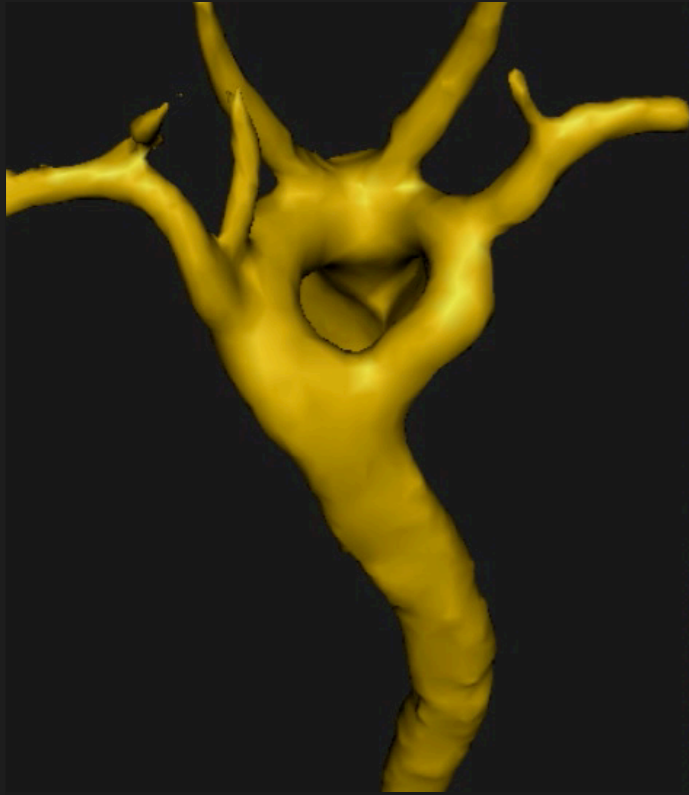
Tri-leaflet valve

## RV dilation

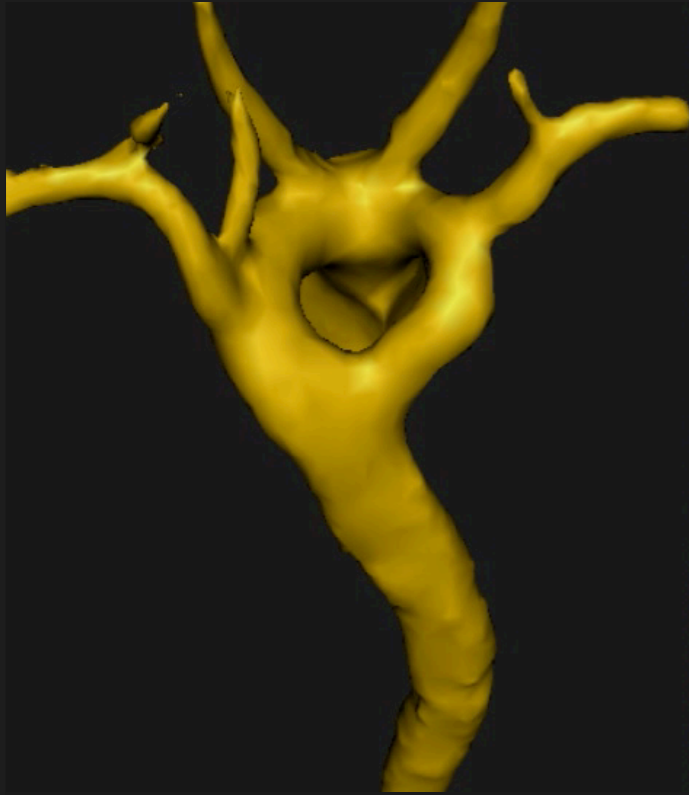
Due to systemic RV failure

TR - Ebsteins

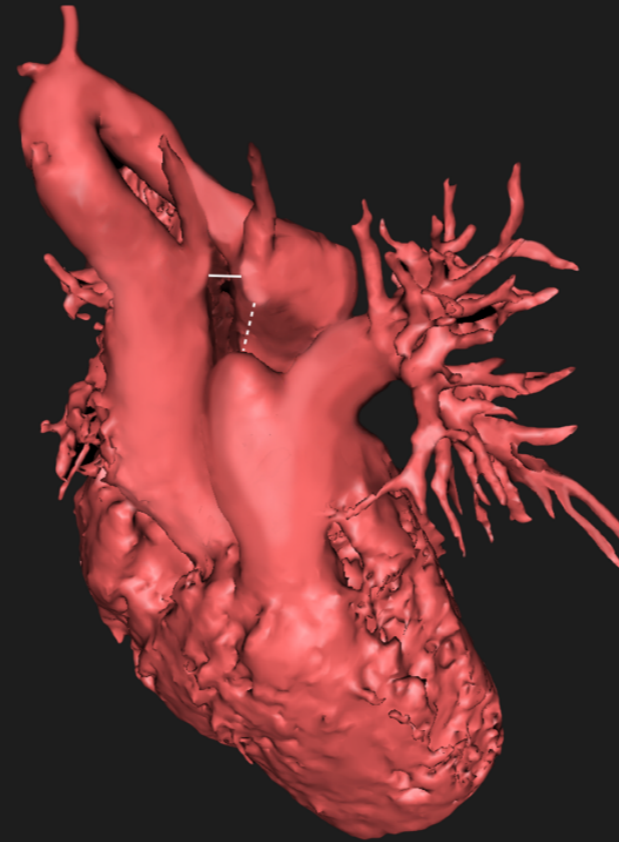
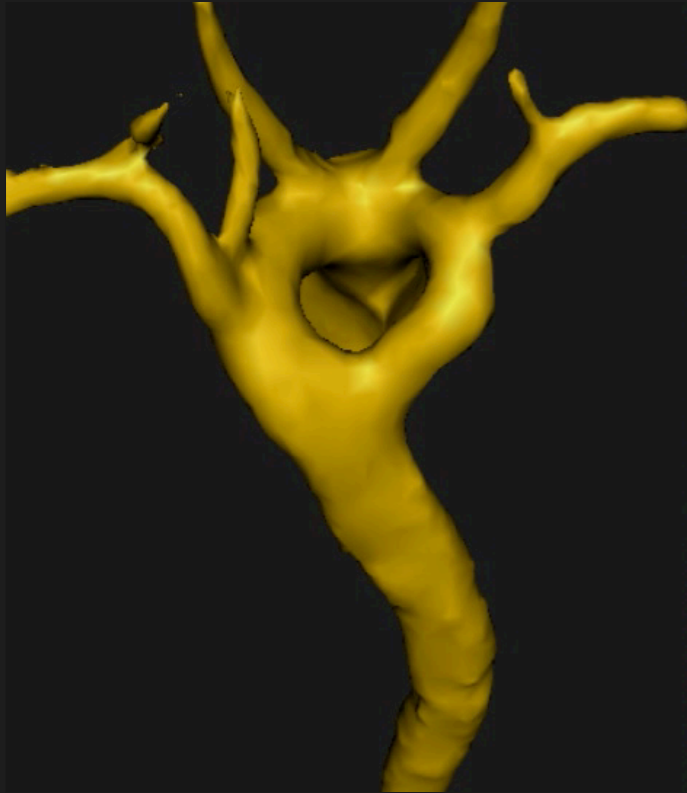
# Vascular Ring



# Vascular Ring

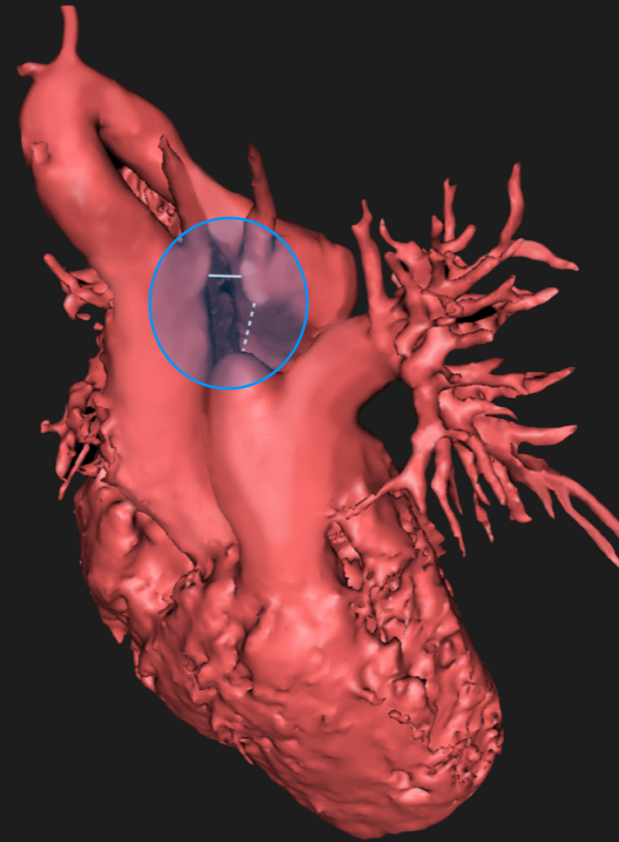
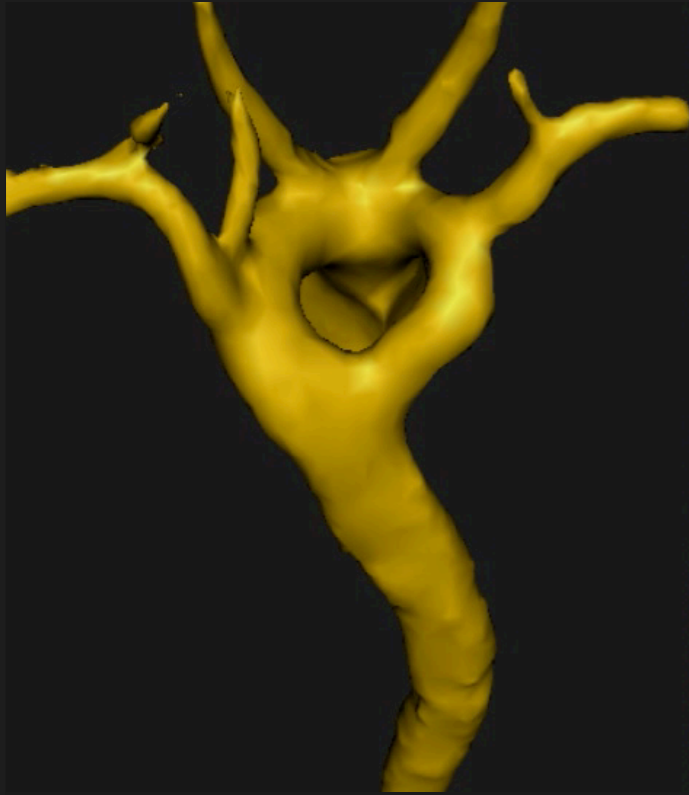


# Vascular Ring



R-arch atretic left

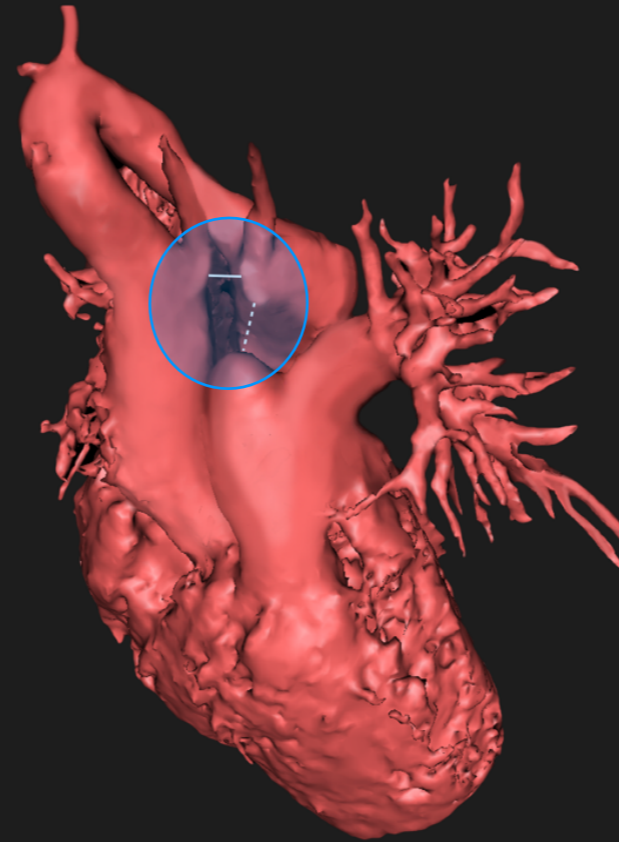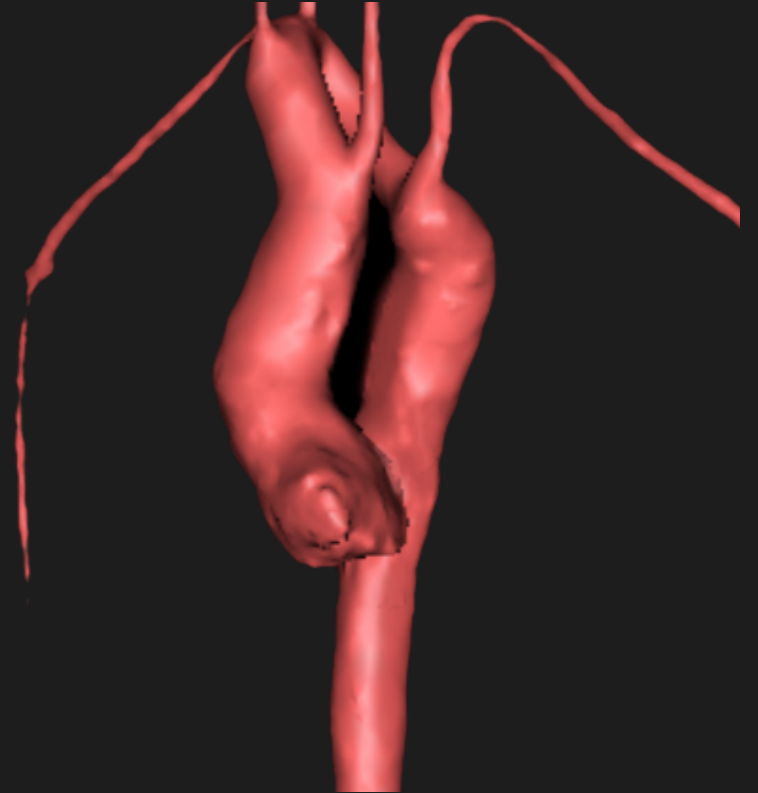
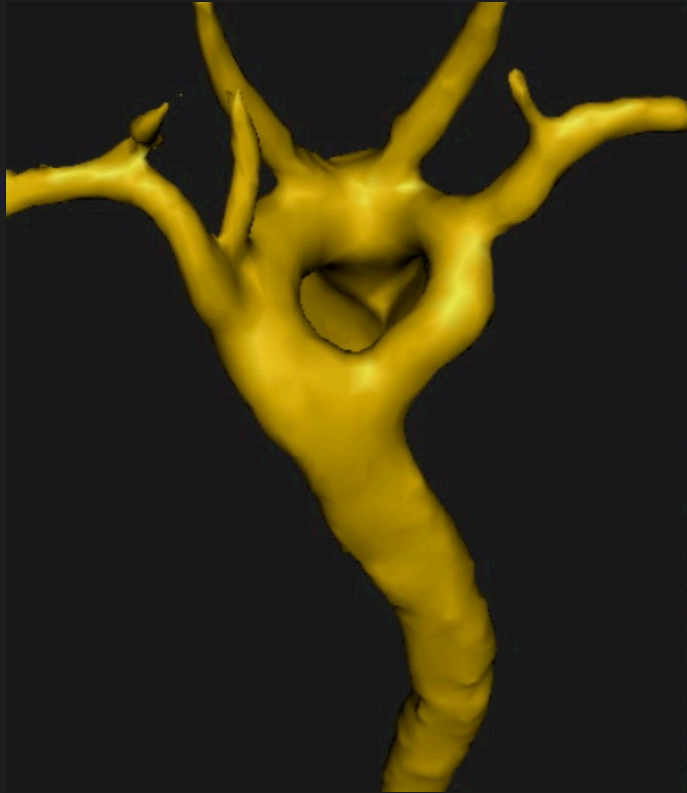
# Vascular Ring



R-arch atretic left



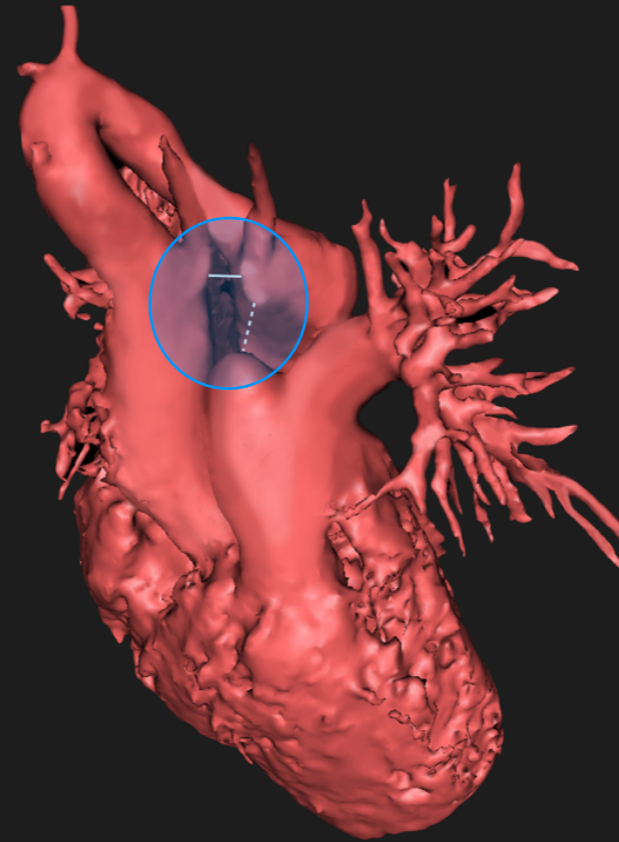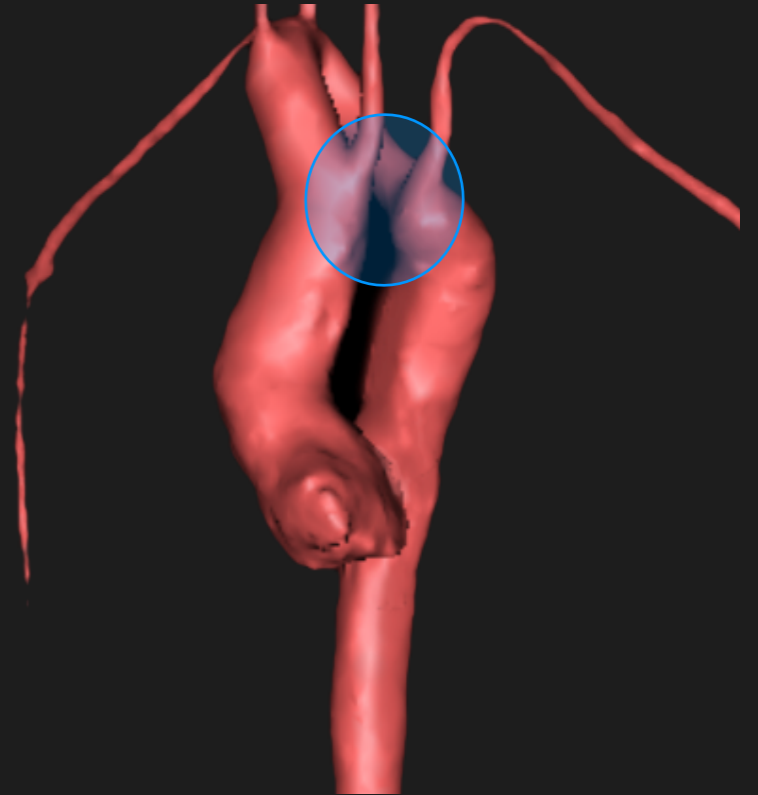
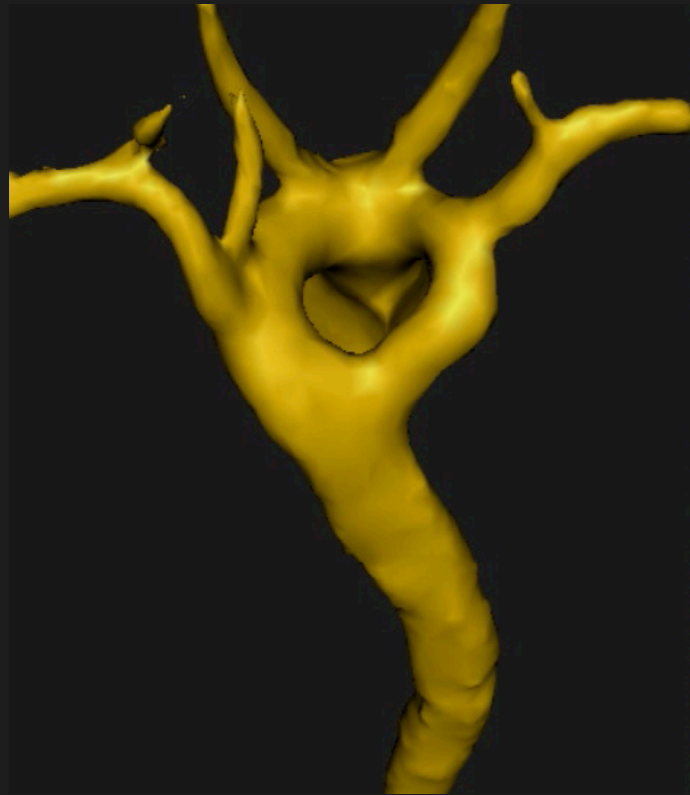# Vascular Ring



R-arch atretic left

Kommerell's

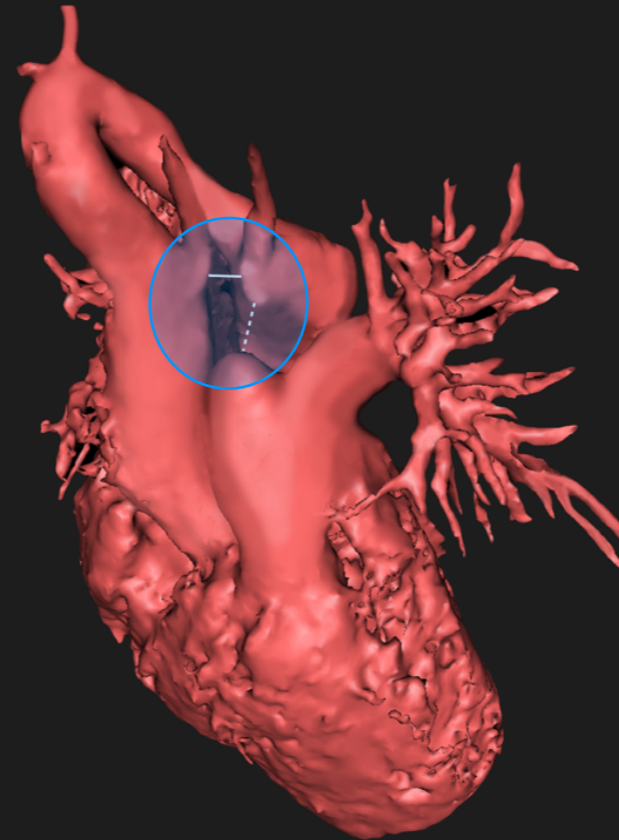
# Vascular Ring



R-arch atretic left

Kommerell's

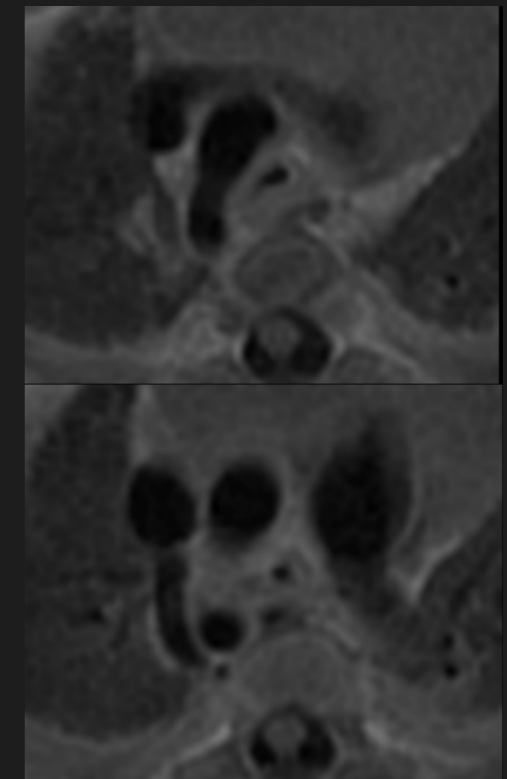
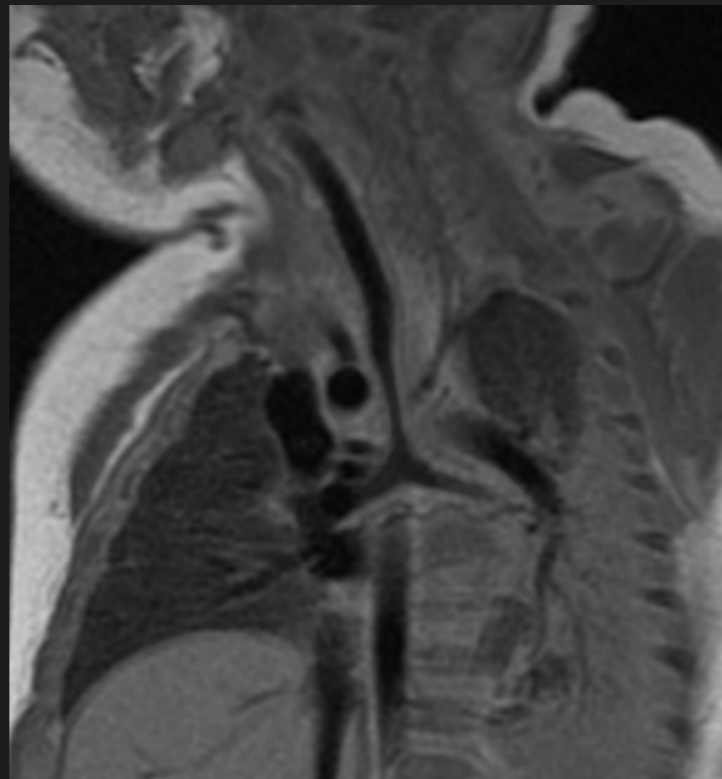
# Vascular Ring



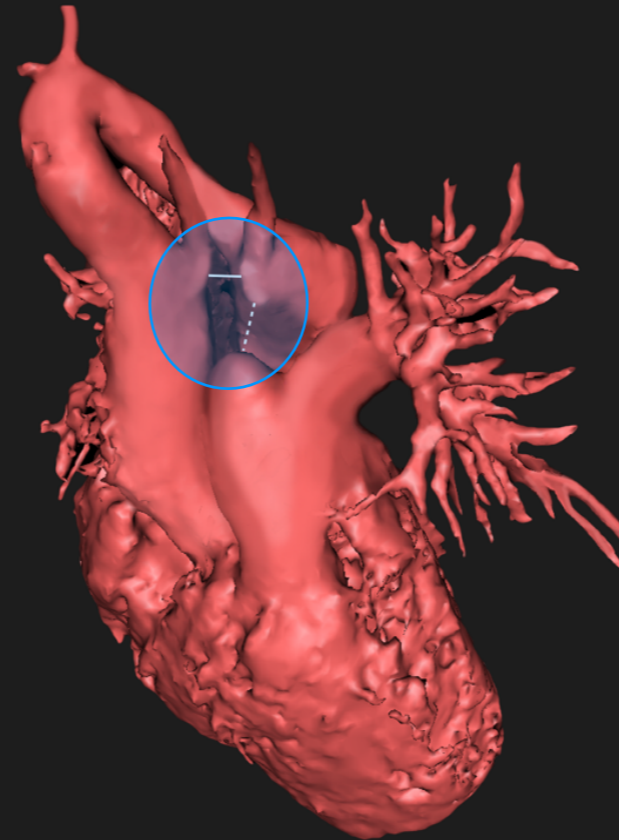
R-arch atretic left

Kommerell's

MR - trachea



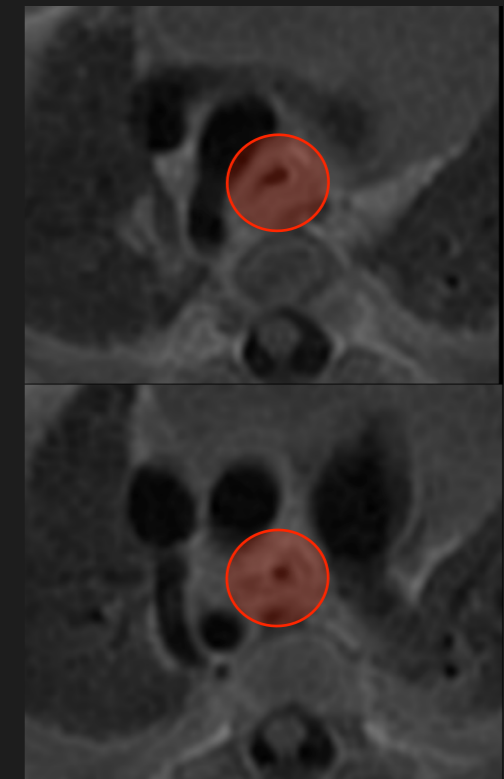
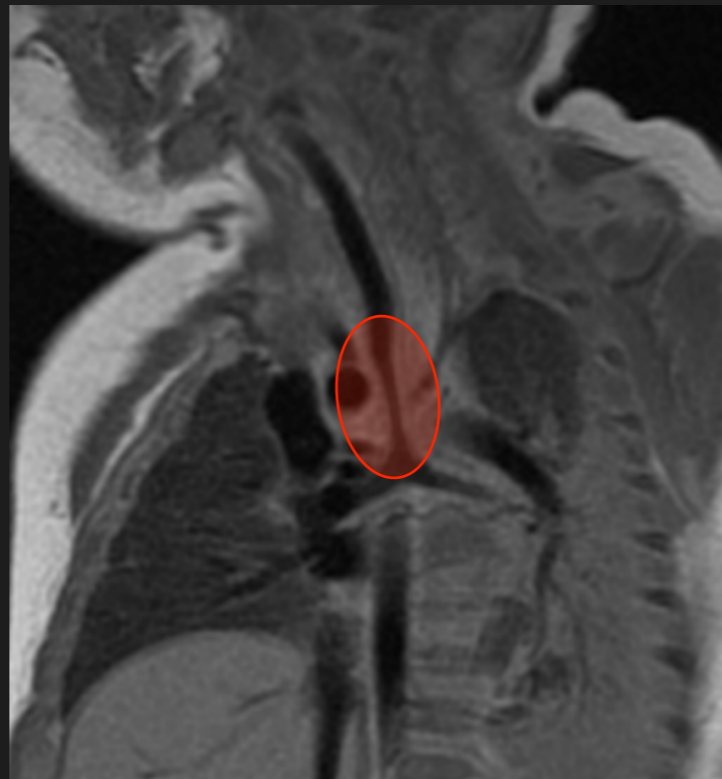# Vascular Ring



R-arch atretic left

Kommerell's

MR - trachea







**Congenital CMR**




**One stop shop**



**Congenital CMR**



Put the data together



One stop shop




**Congenital CMR**





Put the data together

Complex



One stop shop

**Congenital CMR**



